

SPLINTING USING NATURAL TOOTH AS PONTIC

PATIENT NAME: Mr.A.J.

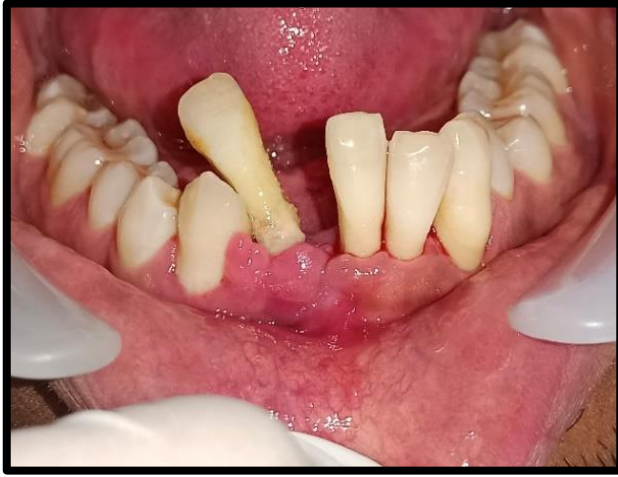AGE: 28

GENDER: M

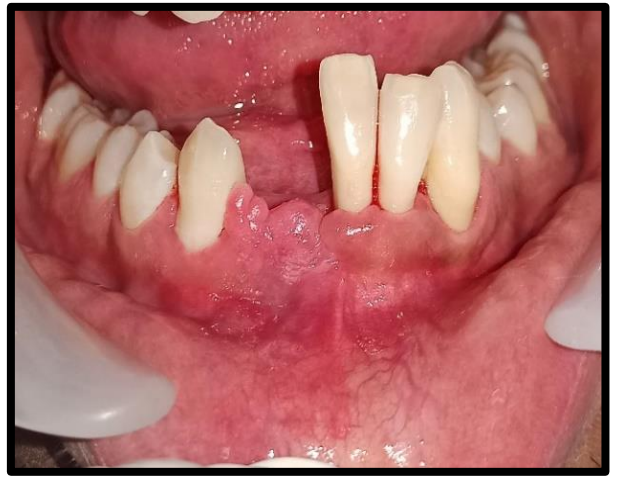OPD NO: 213816

DIAGNOSIS: Generalized dental biofilm induced gingivitis in an intact peridontium with mucogingival deformity and condition with RT 2 31,32 RT 3 with 42.

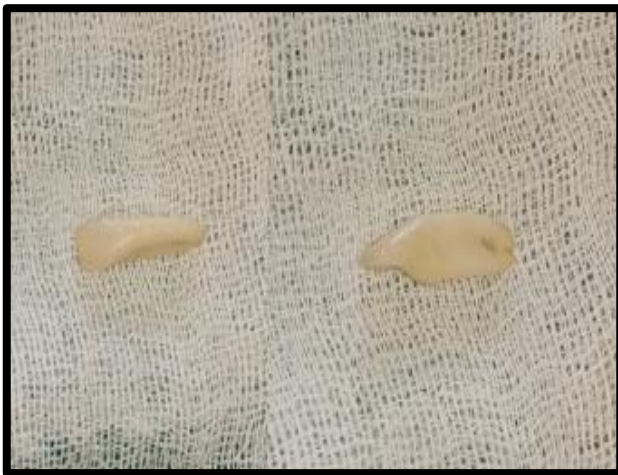TREATMENT DONE: Splinting done using natural tooth as pontic with mandibular anterior teeth.



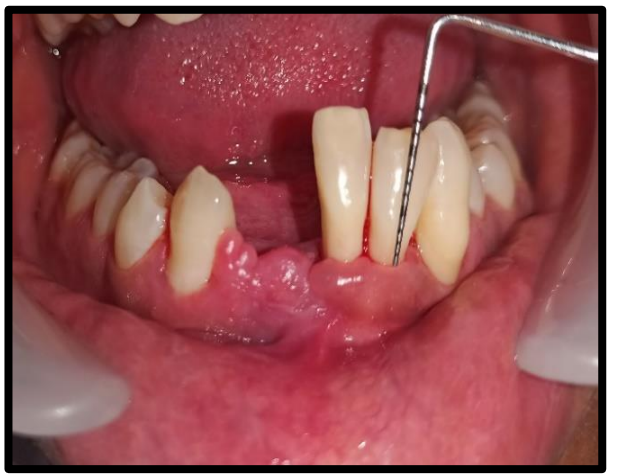**MANDIBULA FRONTAL VIEW
BEFORE EXTRACTION**



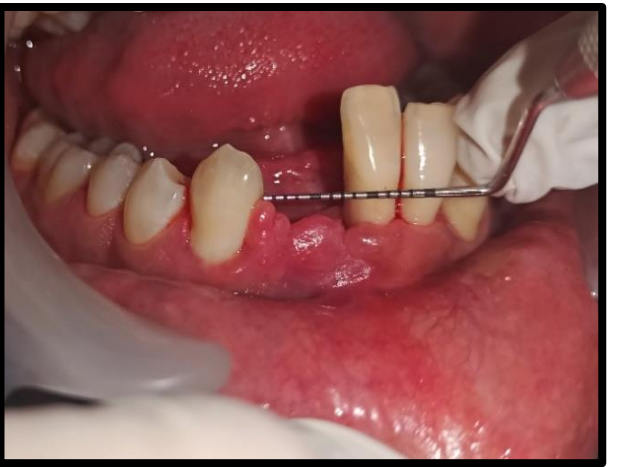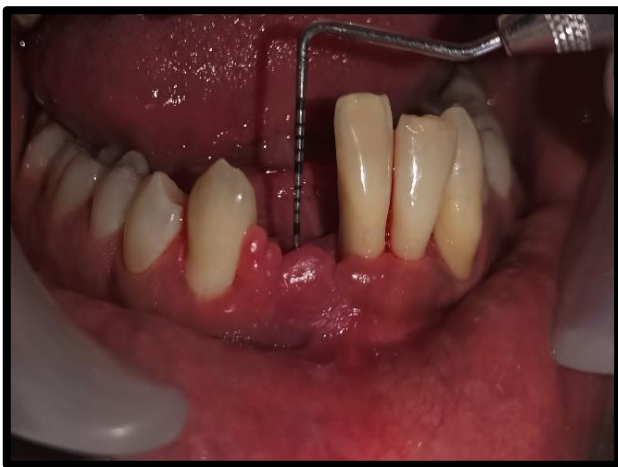**MANDIBULA FRONTAL VIEW
AFTER EXTRACTION W.R.T. 42**



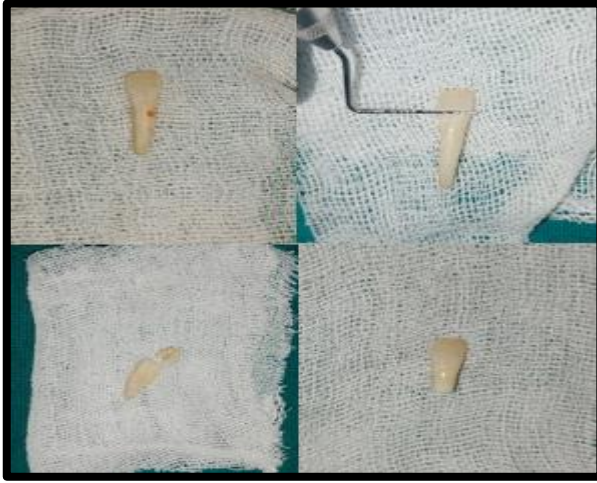NATURAL PONTIC



MESURED LENGTH OF #32



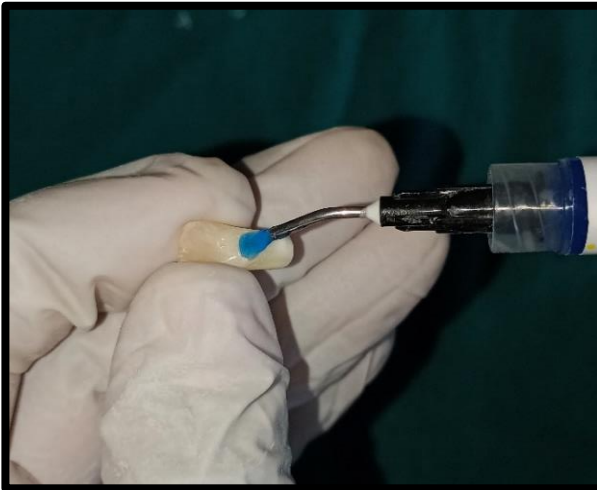
LENGTH AND WIDTH IN EXTRACTION SITE



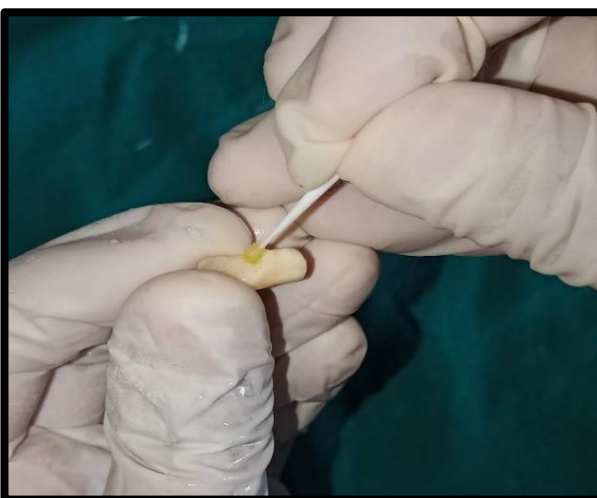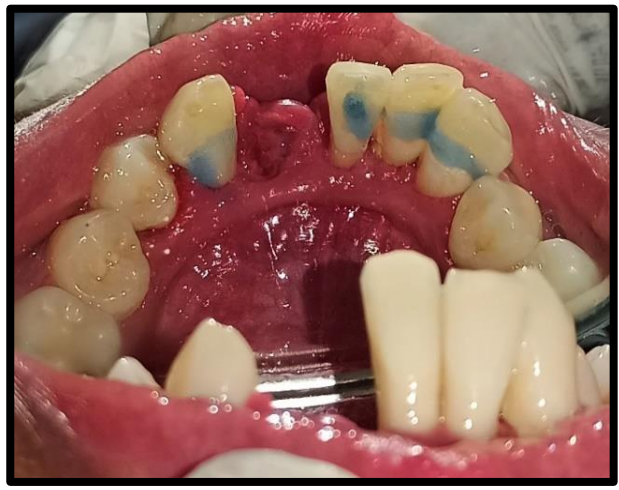CUT THE NATURAL PONTIC



**CANAL WIDNING AND
COMPOSITE FILLING DONE**



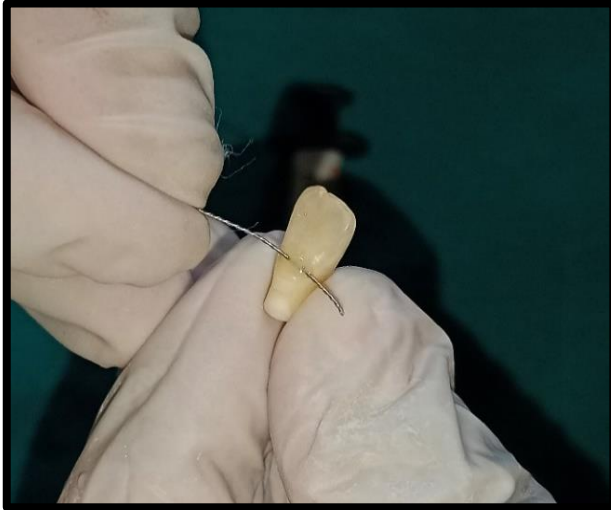APPLICATION OF ETCHANT TO PONTICS AND TEETH



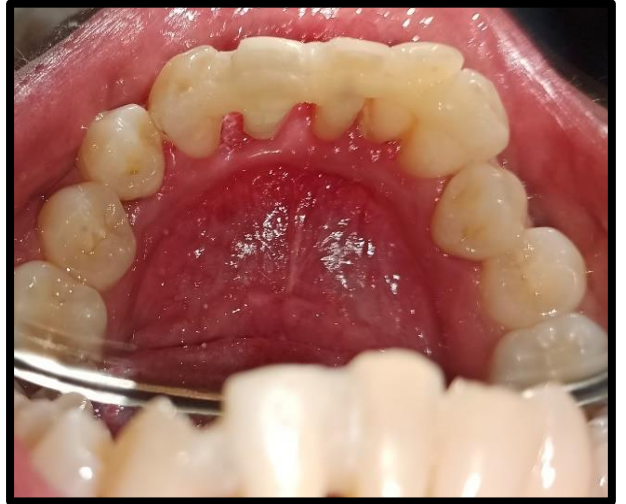BONDING AGENT PPLICATION



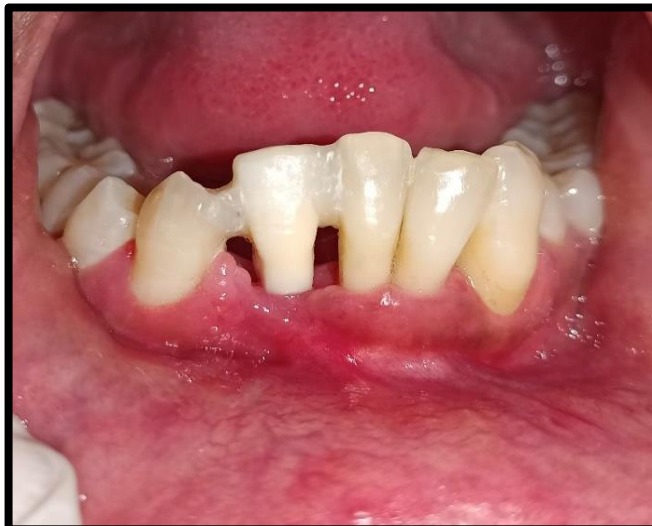LIGHT CURE APPLICATION



**LIGATURE WIRE SPLINT WITH
PONTIC**



**LINGUAL VIEW AFTER
PLACEMENT OF NATURAL
PONTIC**



**AFTER PLACEMENT OF
NATURAL PONTIC**