

## **RIDGE SPLIT & IMPLANT PLACEMENT.**

PATIENT NAME: Ms. S. R.

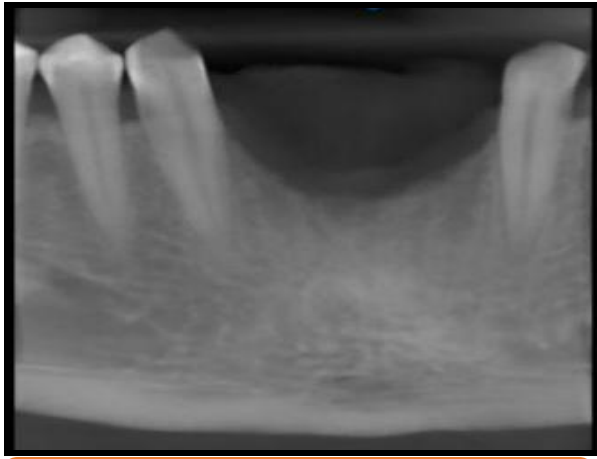
AGE: 33

GENDER: M

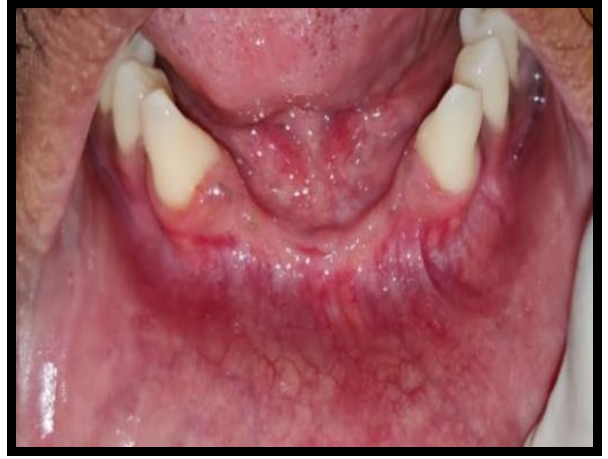OPD NO: 120211

DIAGNOSIS: Generalized periodontitis, Stage III, Grade B, currently unstable, with mucogingival deformity and condition with generalized gingival recession with missing teeth & inadequate alveolar ridge width w r t 31,32,41,42.

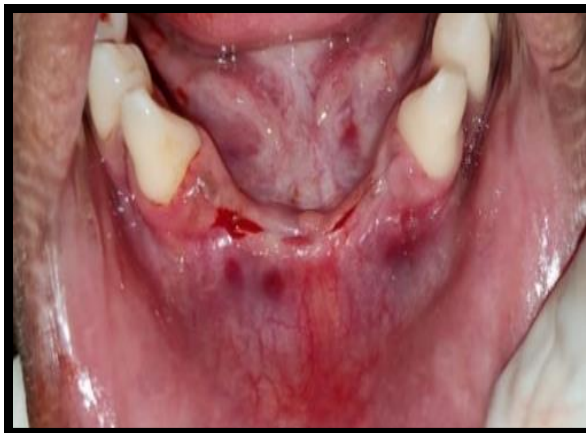TREATMENT DONE: Ridge split & implant placement done with 32, 42.



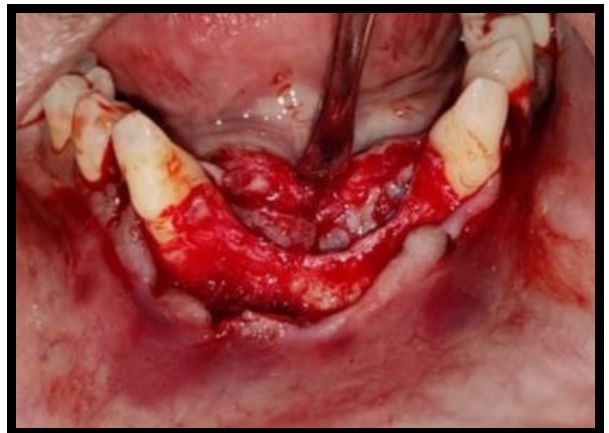
**PREOPERATIVE RVG**



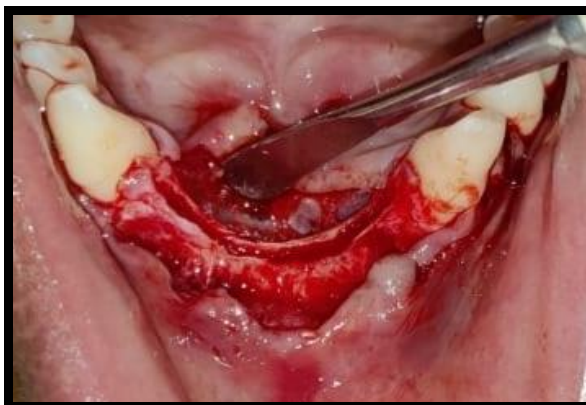**PREOPERATIVE INTRAORAL**



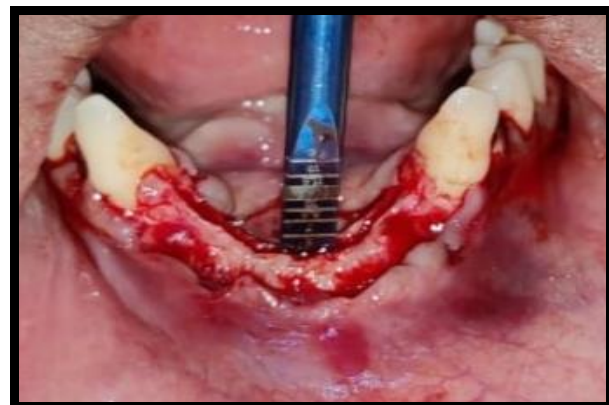**CRESTAL INCISION GIVEN**



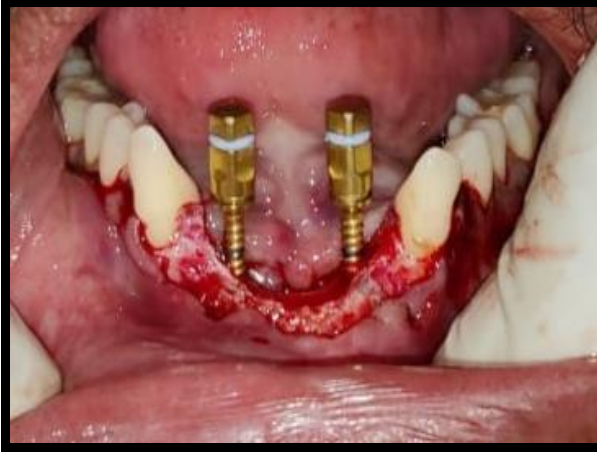**FULL THICKNESS FLAP  
ELEVATION**



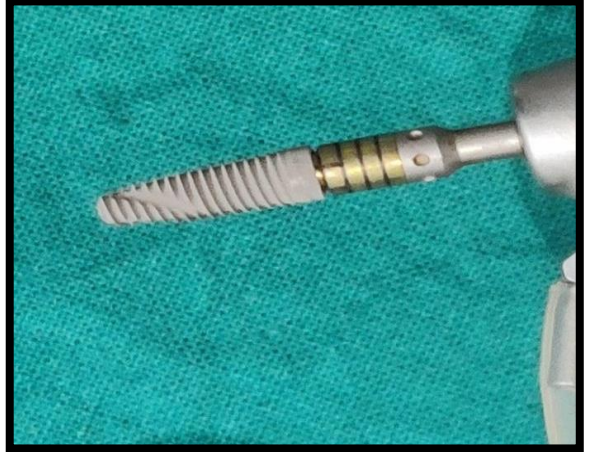**HORIZONTAL GROOVE  
PREPARED ON RIDGE WITH BUR**



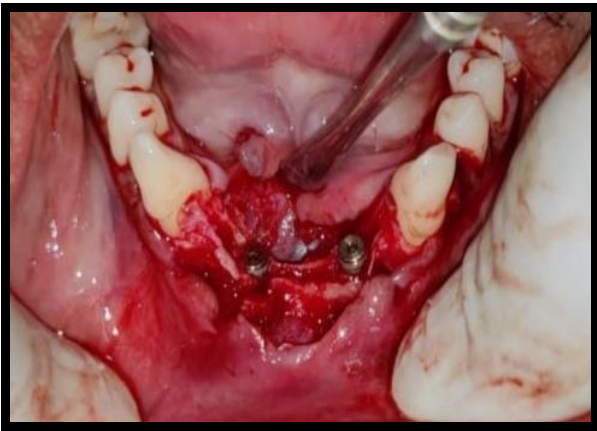**RIDGE SPLIT DONE WITH  
OSSEOTOME**



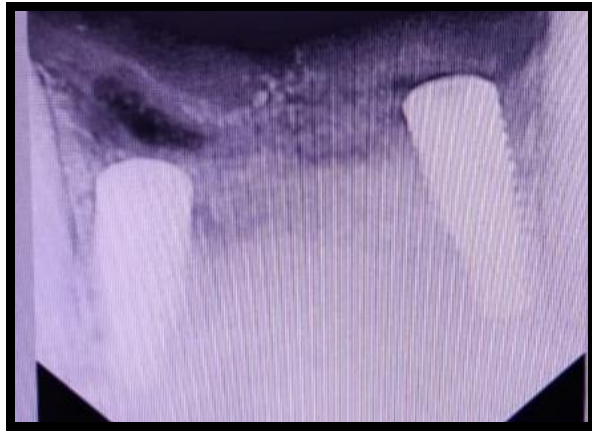**OSTEOTOMY PREPARATION  
DONE WITH BONE EXPANDER**



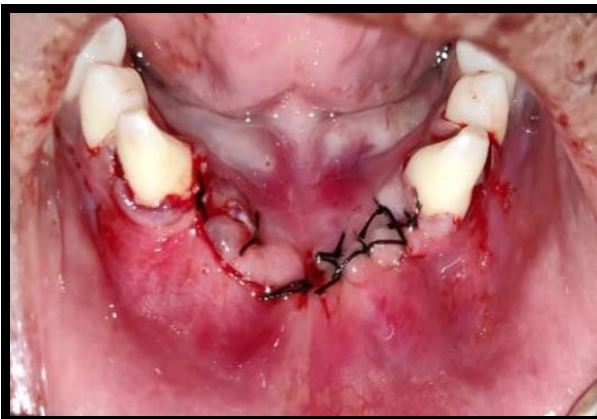**IMPLANT SIZE 3.75 x 10 SELECTED**



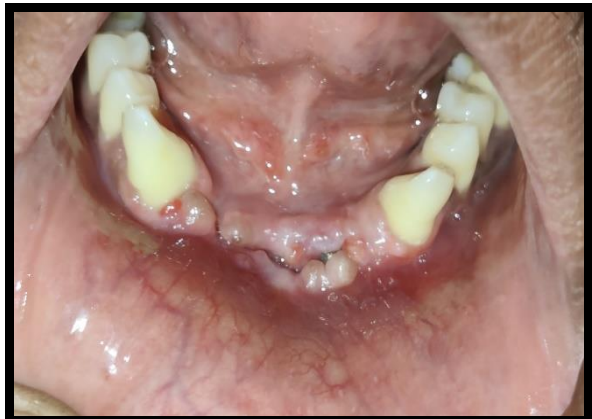**IMPLANT & COVER SCREW  
PLACEMENT.**



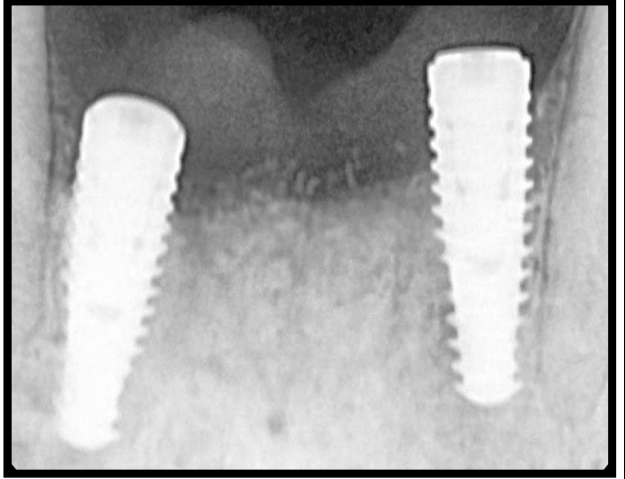
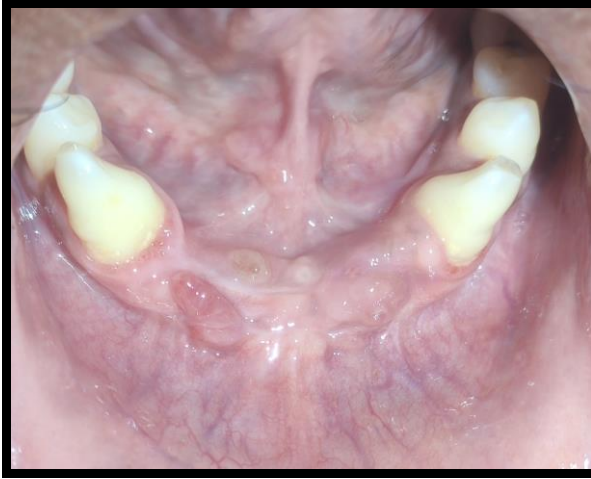**POST OPERATIVE RVG**



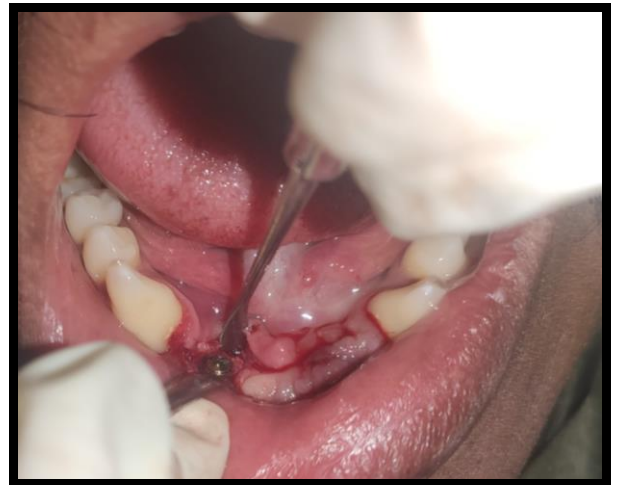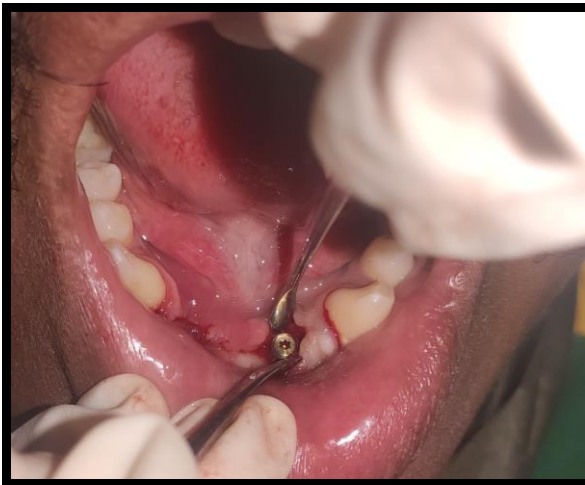**SIMPLE INTERRUPTED SUTURE**



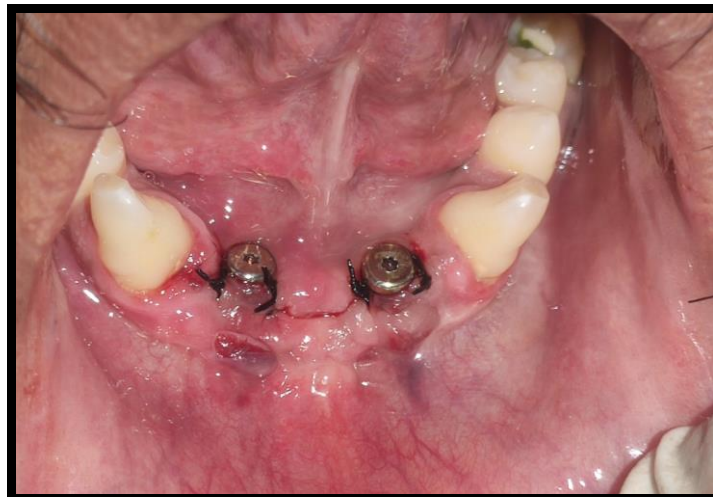**15 DAYS FOLLOW UP**



**FOUR MONTH FOLLOW UP**



**STAGE II IMPLANT SURGERY**



**HEALING ABUTMENT PLACEMENT**