

HEMISECTION

PATIENT NAME: Mrs. L.T.

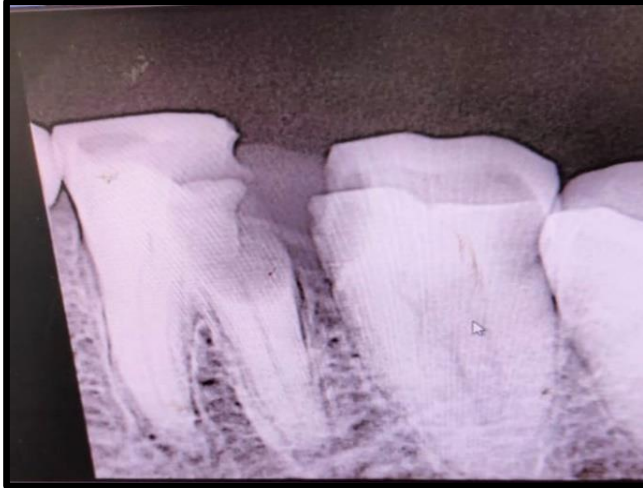
AGE: 40

GENDER: F

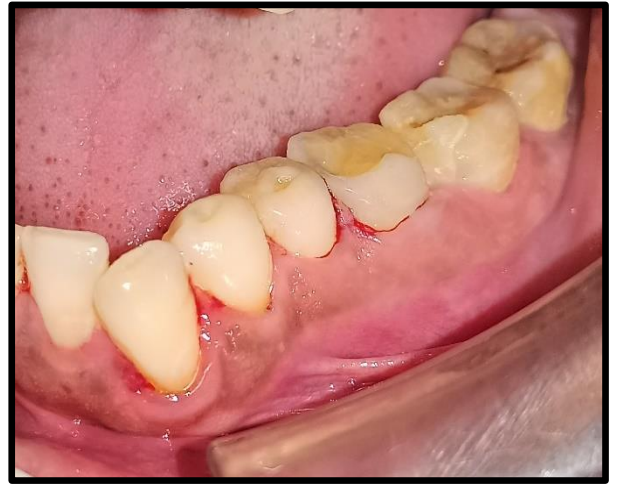OPD NO: 213678

DIAGNOSIS: Generalized dental biofilm induced gingivitis on an intact periodontium with endo-periodontal lesion with root damage with 36

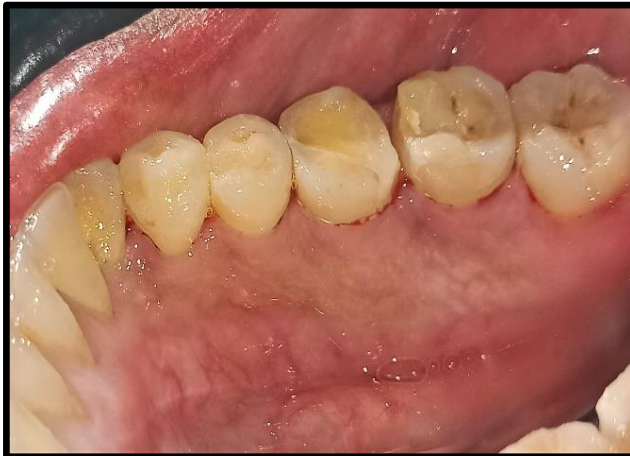TREATMENT DONE: Hemisection with 36



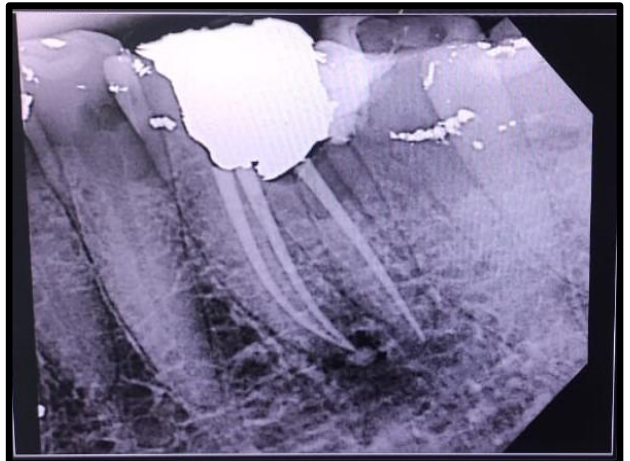
IOPA W.R.T. 36



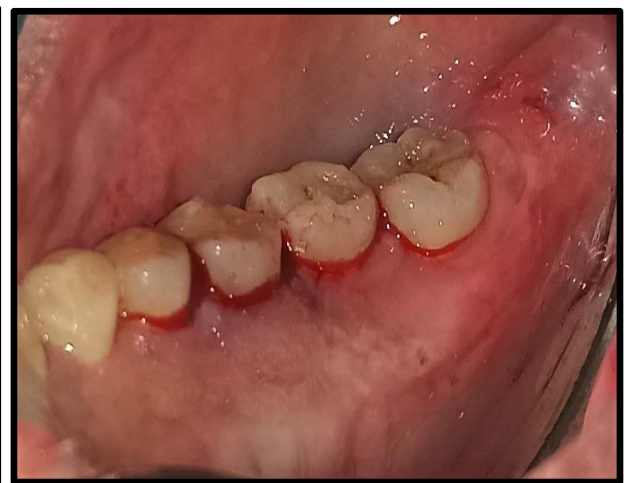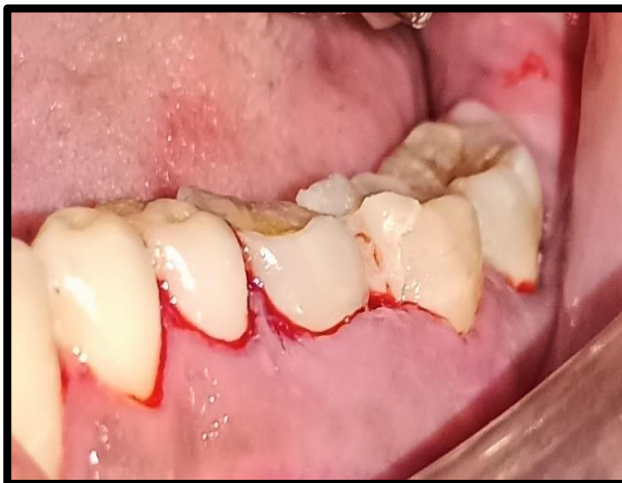MANDIBULAR LEFT BUCAL VIEW



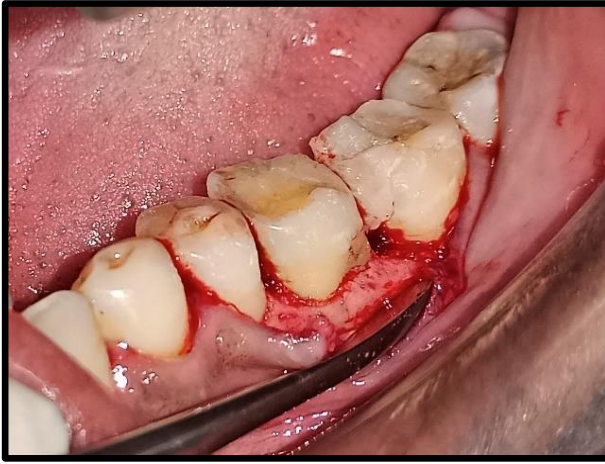**MANDIBULAR LEFT LINGUAL
VIEW**



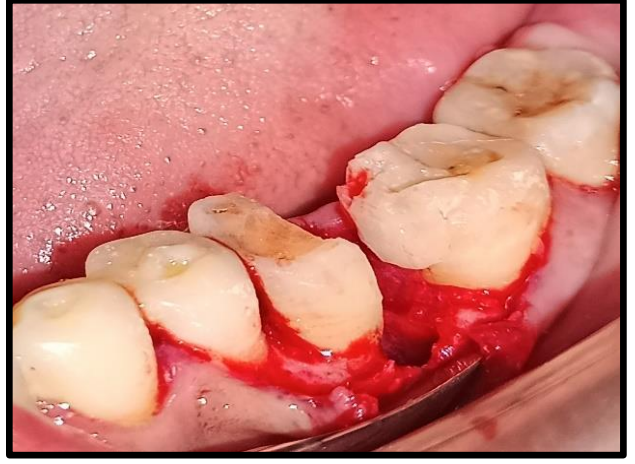**IOPA AFTER ROOT CANAL
TREATMENT #36**



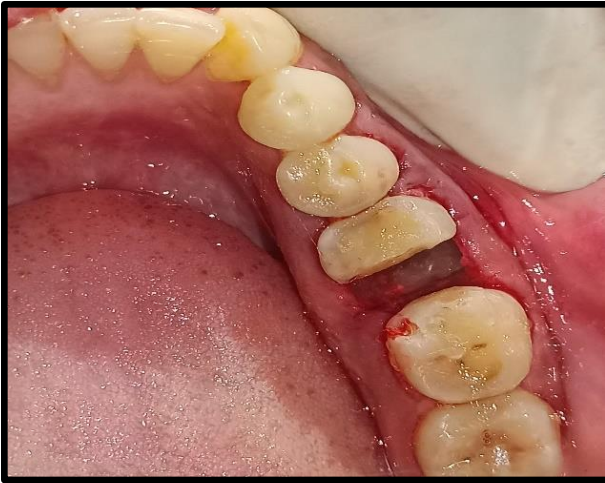INTRASULCULAR INCISION GIVEN BY #12 BLADE



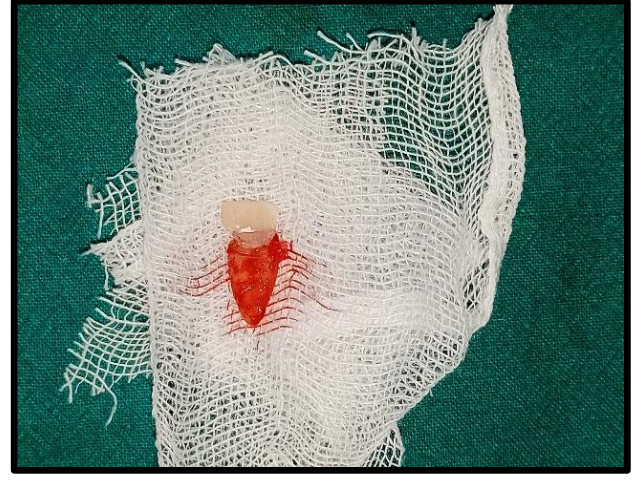
**FULL THICKNESS FLAP
REFLECT**



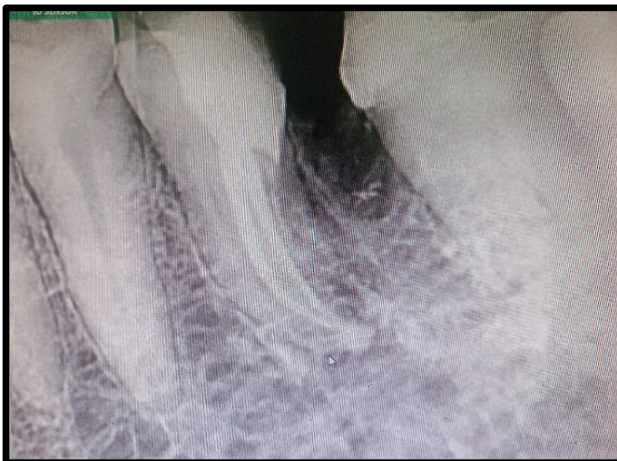REMOVE DISTAL ROOT WRT.36



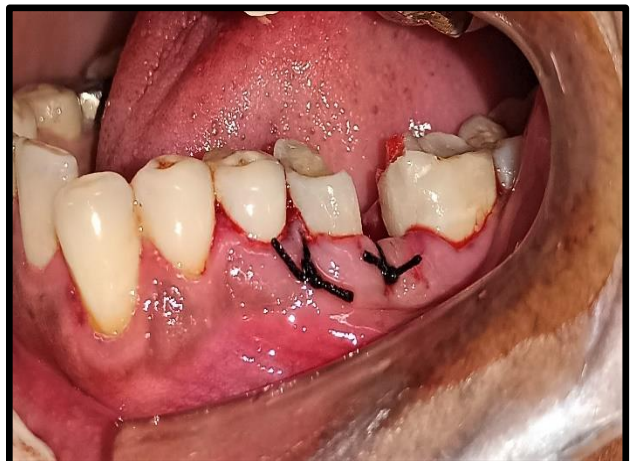EXTRACTION SOCKET



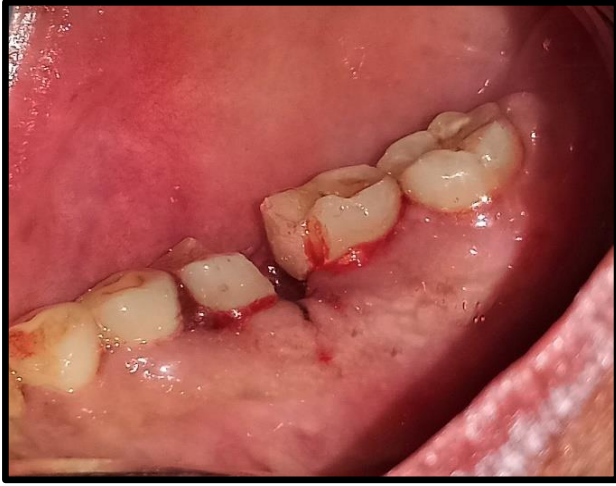**EXTRACTED CROWN AND
ROOT**



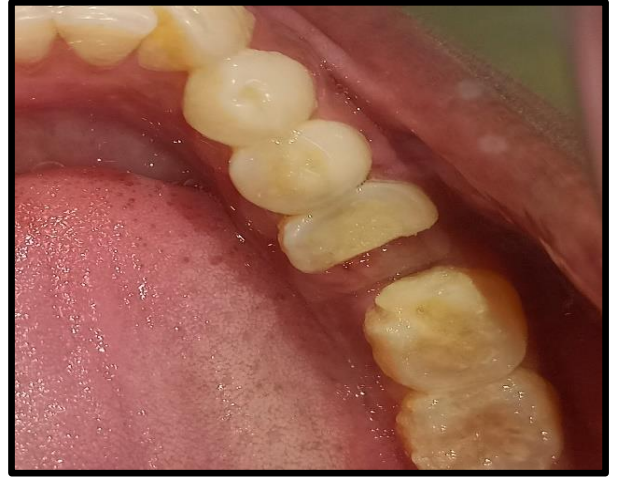IOPA AFTER HEMISECTION



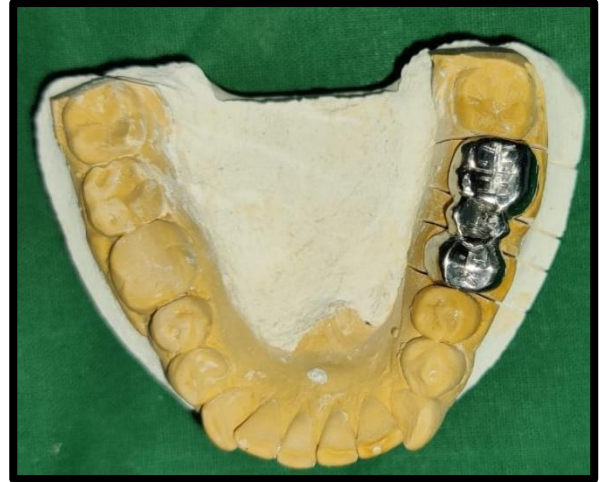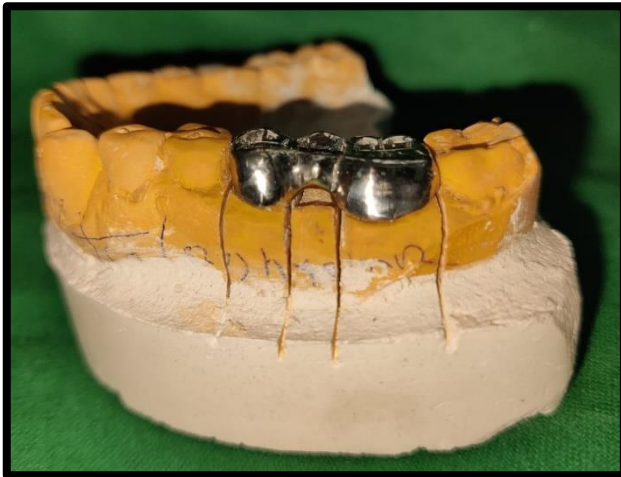INTERUPTED SUTURES GIVEN



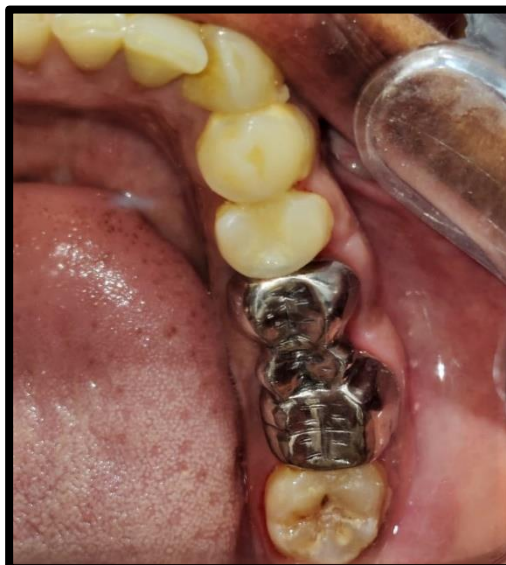LINGUAL VIEW AFTER SUTURING



15 DAYS FOLLOW UP



PROSTHESIS ON CAST



**FINAL
PROSTHESIS**