

## **VESTIBULAR DEEPENING IN IMPLANT PATIENT**

PATIENT NAME: Mr. S. R.

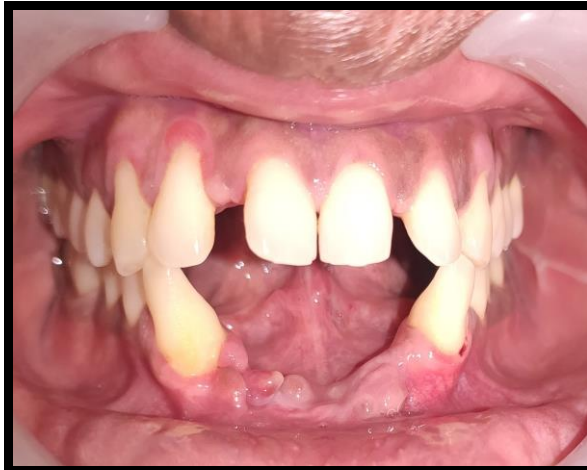AGE: 33

GENDER: M

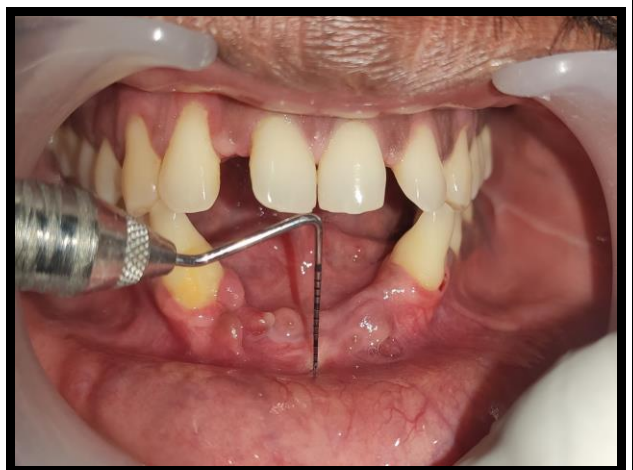
OPD NO: 120211

DIAGNOSIS: Dental biofilm induced gingivitis in reduced periodontium with mucogingival deformity and condition with gingival recession of RT 2 with 33, 43 & lack of keratinized gingiva and decreased vestibular depth with mandibular labial vestibule.

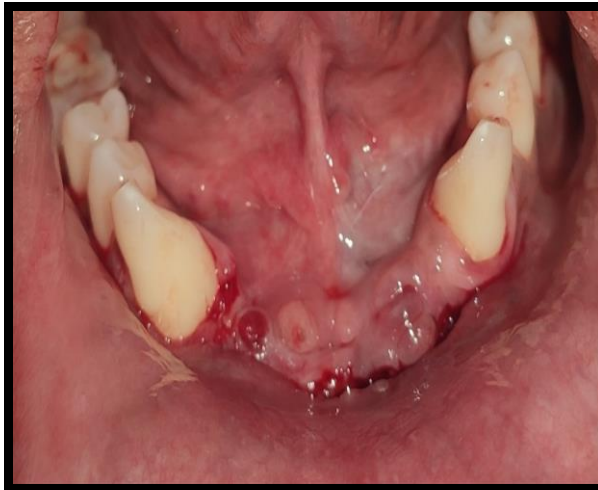TREATMENT DONE: Vestibular deepening procedure with mandibular labial vestibule.



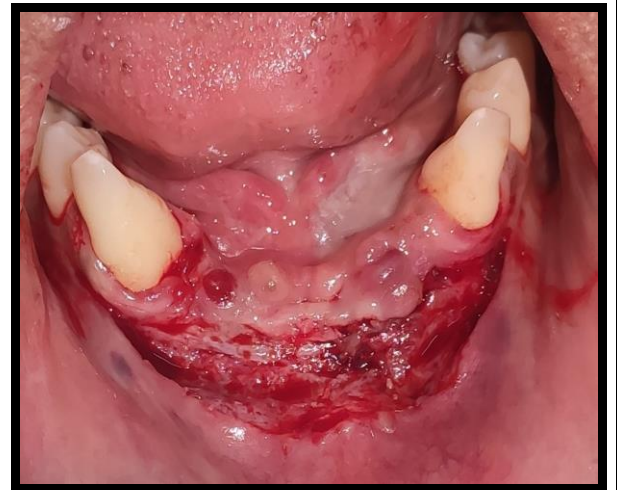
**PREOPERATIVE VIEW**



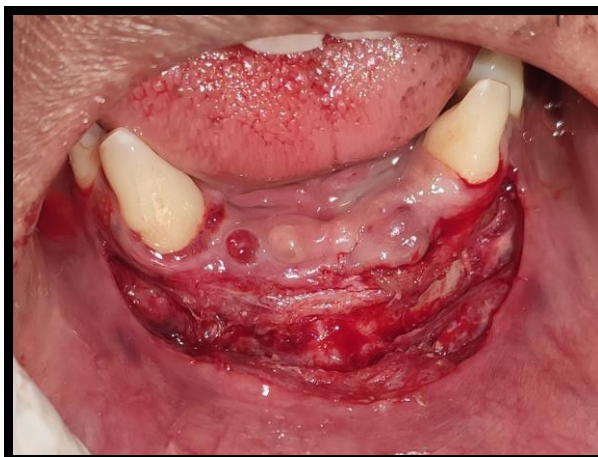**SHALLOW VESTIBULAR DEPTH**



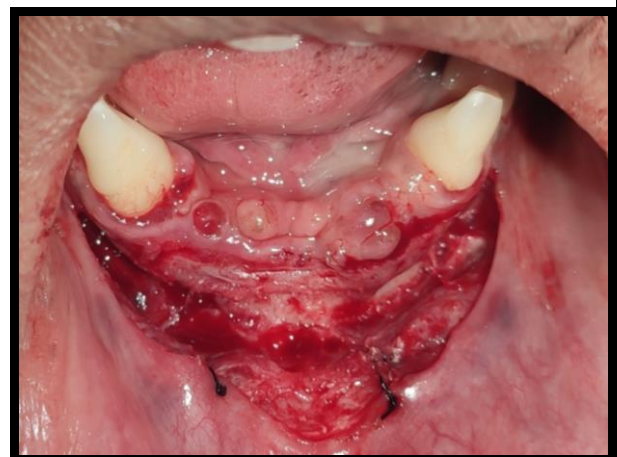
**HORIZONTAL INCISION GIVEN**



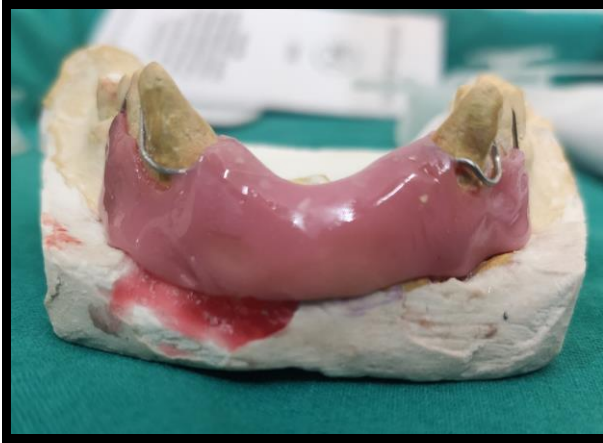**PARTIAL THICKNESS FLAP  
RAISED TILL 4 MM FROM  
INCISION**



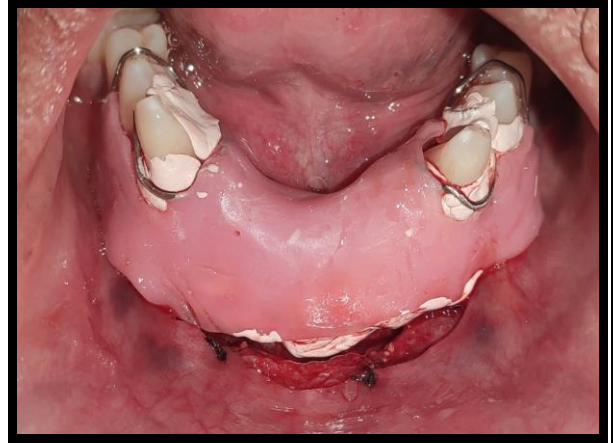**FULL THICKNESS FLAP RAISED  
TILL 4 MM FROM INCISION**



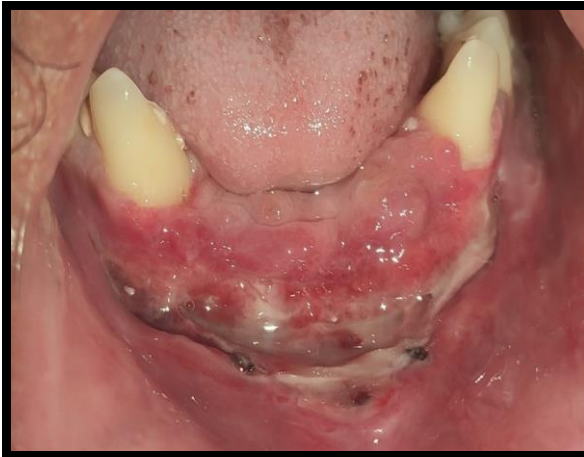**PARTIAL THICKNESS FLAP  
RAISED & PERIOSTEAL SUTURES  
PLACED**



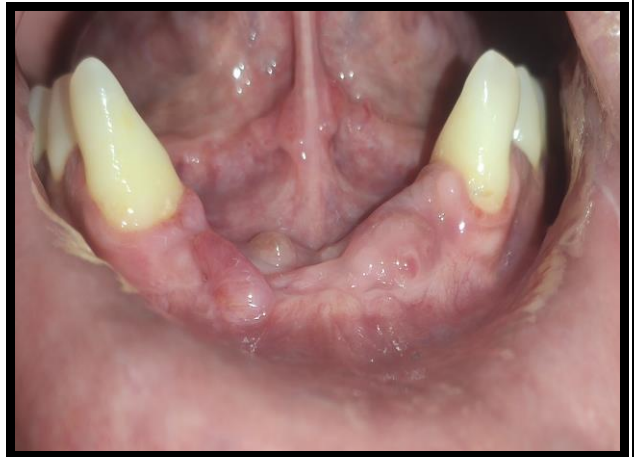**ACRYLIC STENT PREPARED**



**COE-PACK & ACRYLIC STENT  
PLACEMENT AT SURGICAL SITE.**



**15 DAYS FOLLOW UP**



**1 MONTH FOLLOW UP**