

ROOT COVERAGE WITH FREE GINGIVAL GRAFT

PATIENT NAME: Mrs. L. P.

AGE: 38 years

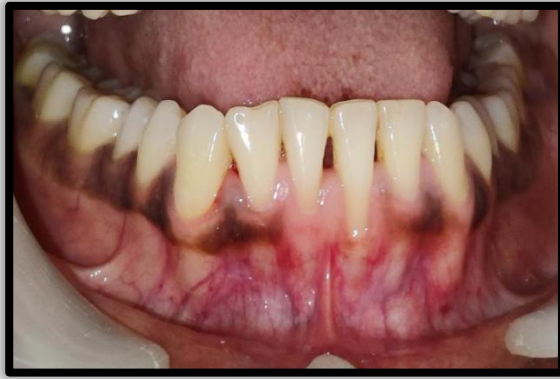GENDER: F

OPD NO: 233239

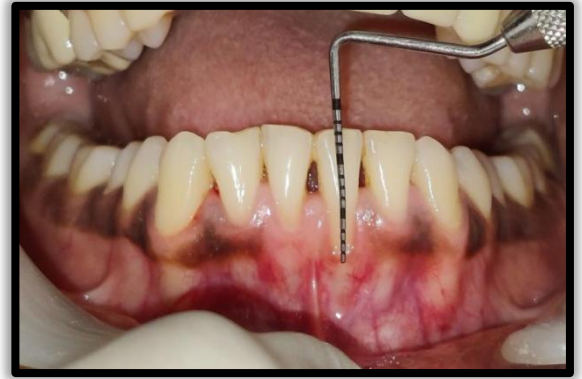DIAGNOSIS: Generalised periodontitis stage III grade B. currently unstable, no risk factors, with mucogingival deformities and conditions of RT 1 recession wrt 41 and RT 2 recession wrt 31, with lack of keratinized gingiva wrt 31

TREATMENT DONE: Free gingival graft wrt 31 and 41

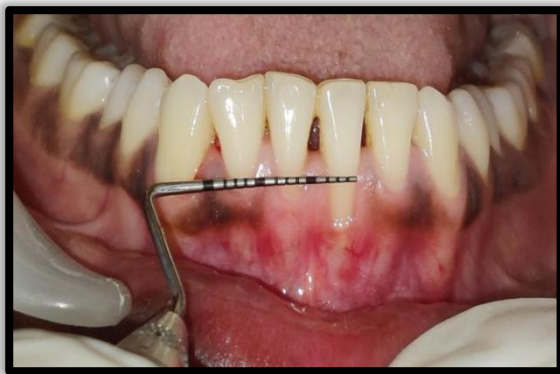ROOT COVERAGE BY FREE GINGIVAL GRAFT



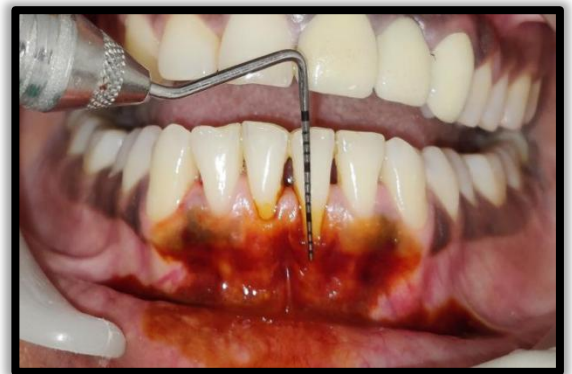**PRE-OPERATIVE FRONTAL
VIEW**



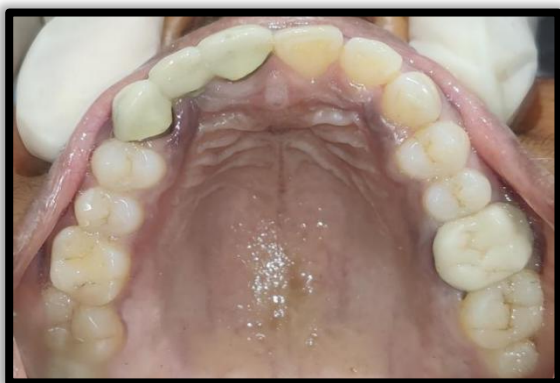RECESSION HEIGHT = 5 MM



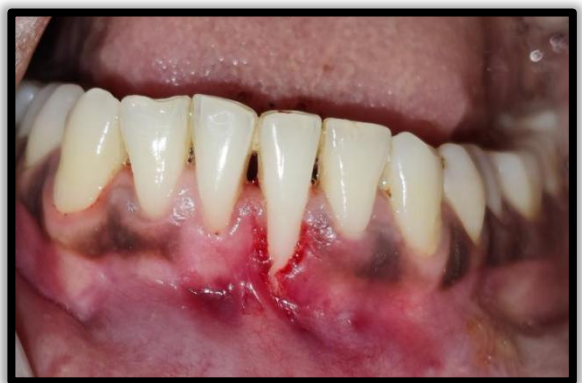RECESSION WIDTH = 3 MM



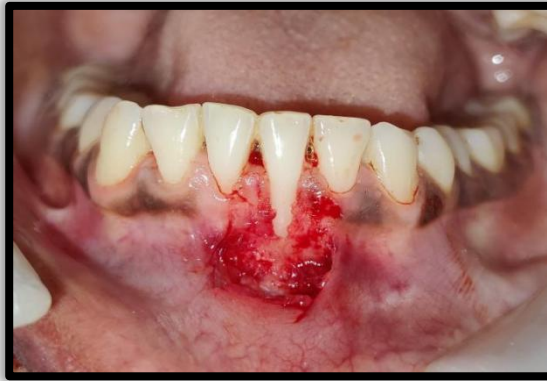**STAINING WITH LUGOL'S
IODINE**



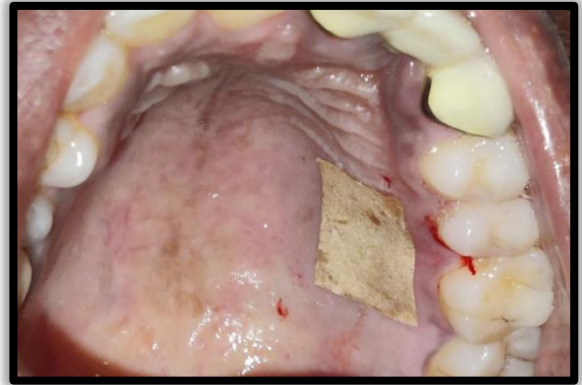
PALATAL VIEW



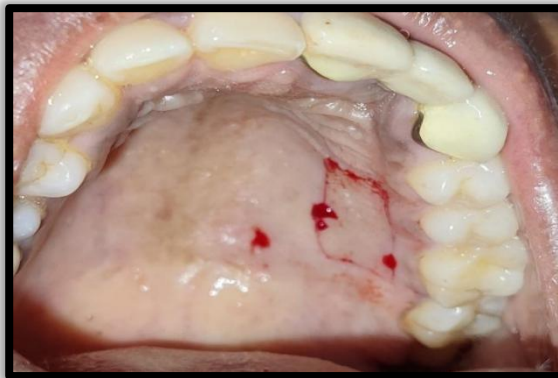
**RECESSION DEFECT WRT #31
AFTER ROOT PLANING**



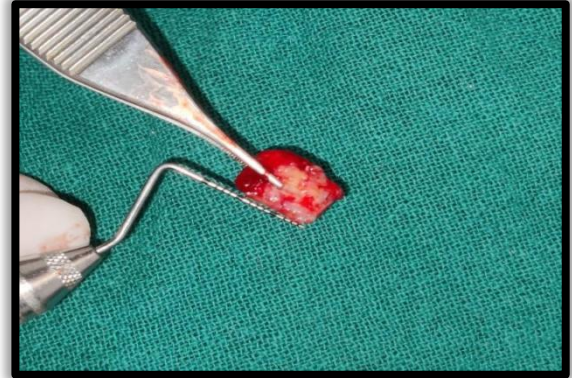**2 HORIZONTAL INCISION
TRACED 1MM CORONAL TO
CEJ AND EXTENDING 3MM
MESIO-DISTALLY AND TWO
VERTICAL INCISION DIVERGING
IN CORONOAPICAL DIRECTION**



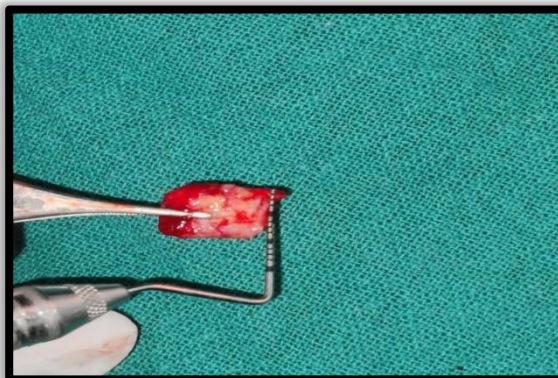TEMPLATE PLACED



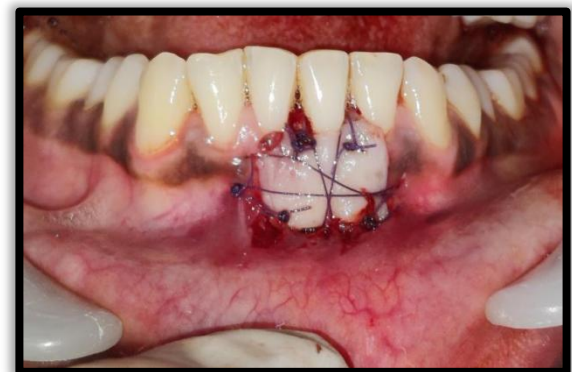**TWO HORIZONTAL INCISION
AND TWO RELEASING INCISION
GIVEN WITH PALATAL ASPECT**



GRAFT HEIGHT = 11MM

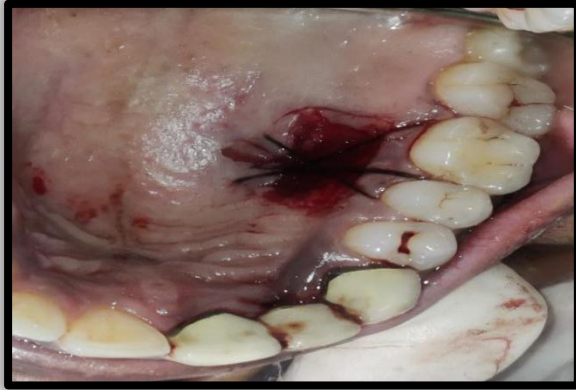

GRAFT WIDTH = 8 MM

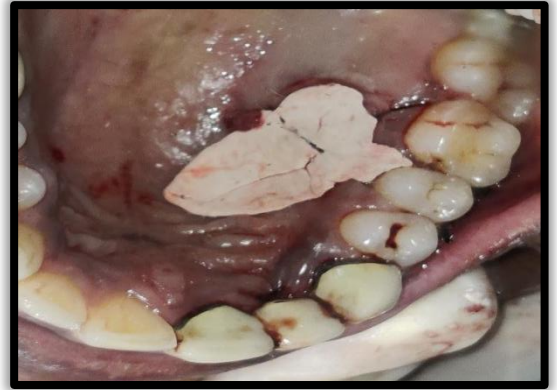

**INTERDENTAL CONCAVITY
AND INTERRUPTED SUTURE
PLACED WITH 5-0 RESORABLE
VICRYL SUTURE**

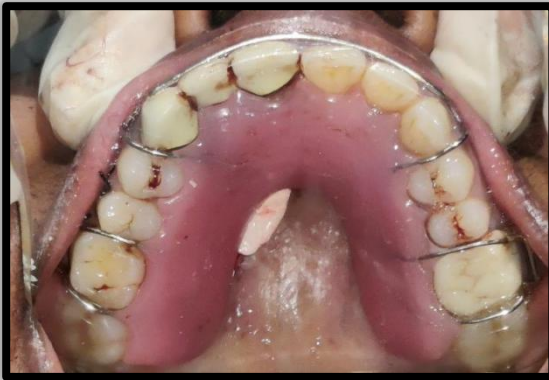ROOT COVERAGE BY FREE GINGIVAL GRAFT



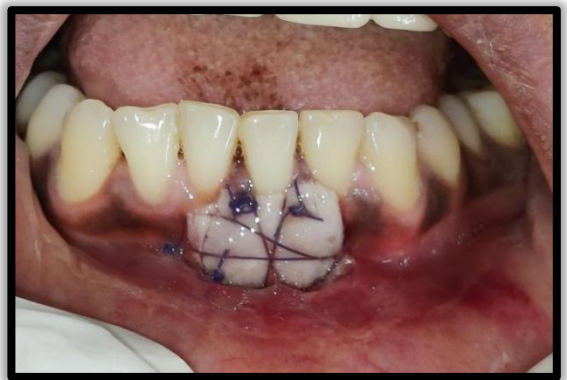**SUSPENSORY SUTURE PLACED
OVER DONOR SITE**



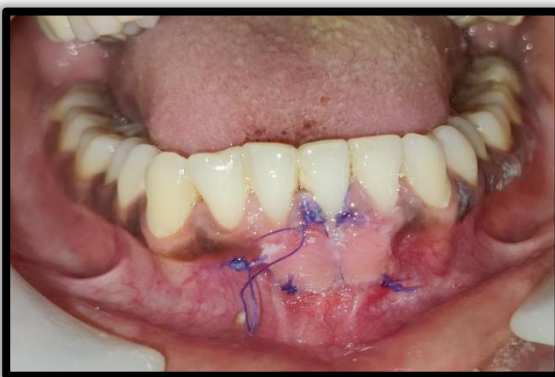**COE PACK PLACED OVER
DONOR SITE**



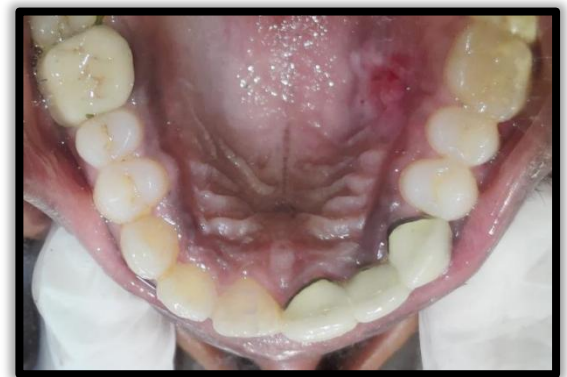**HAWLEY APPLIANCE PLACED
OVER DONOR SITE**



**1 DAY AFTER SURGICAL
PROCEDURE**

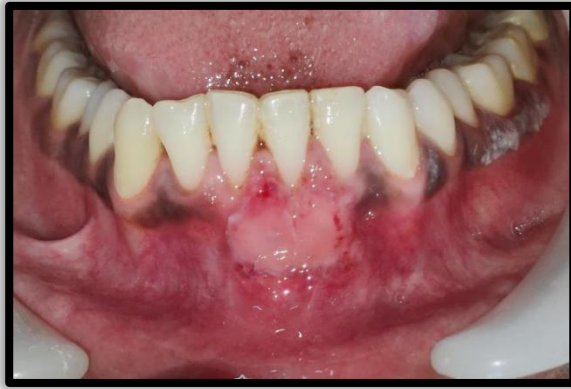

**15 DAYS BEFORE SUTURE
REMOVAL**

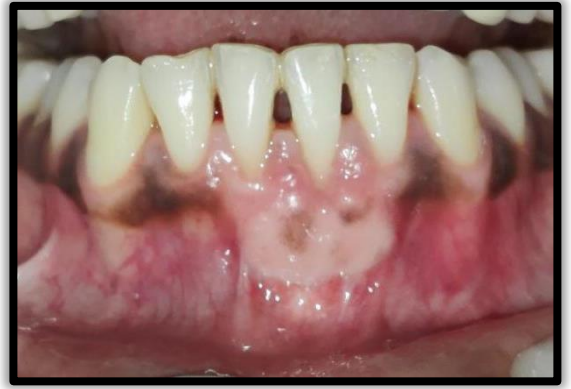

**15 DAYS PALATAL VIEW AFTER
SUTURE REMOVAL**

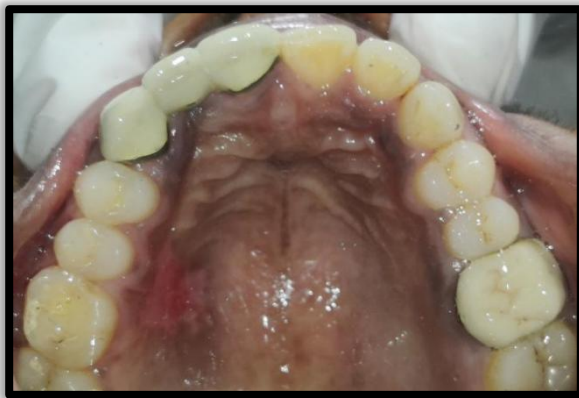ROOT COVERAGE BY FREE GINGIVAL GRAFT



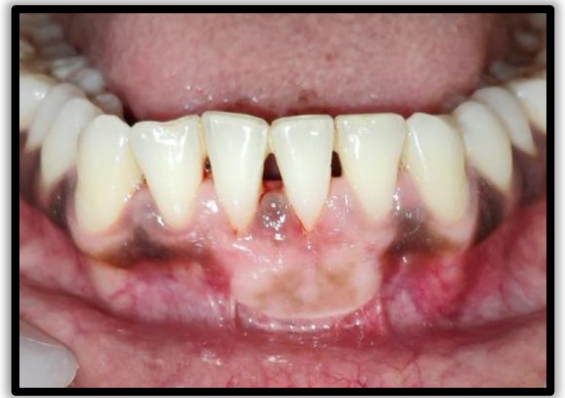**15 DAY FOLLOW UP AFTER
SUTURE REMOVAL**



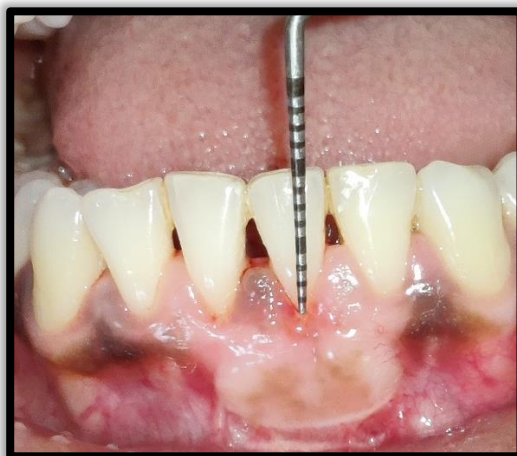1 MONTH FOLLOW UP



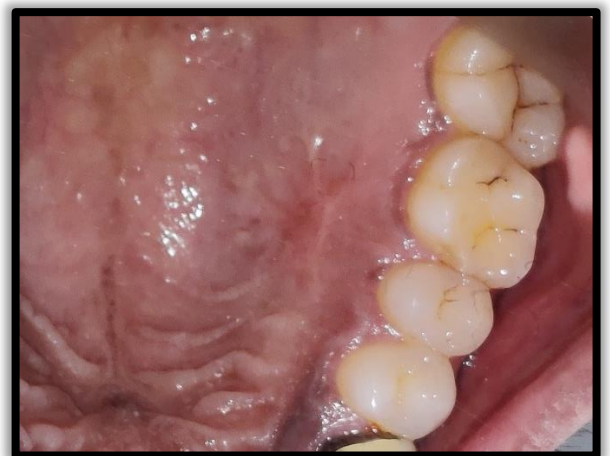**1 MONTH FOLLOW UP WITH
PALATAL VIEW**



4 MONTH FOLLOW UP



4 MONTH FOLLOW UP WITH



**4 MONTH FOLLOW UP WITH
PALATAL VIEW**