

## **PARTIAL EXTRACTION WITH IMPLANT PLACEMENT**

PATIENT NAME: Mrs. R. K.

AGE:29

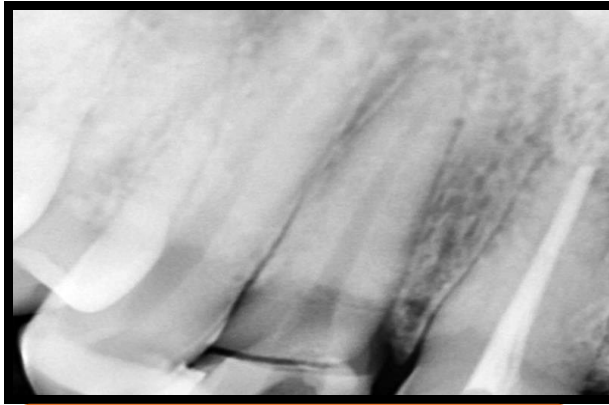GENDER: F

OPD NO: 207222

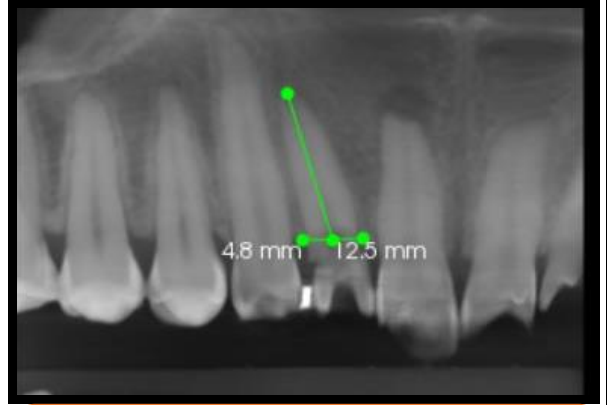
DIAGNOSIS: Dental biofilm induced generalised gingivitis with intact periodontium.

Other diagnosis: Non restorable horizontal cervical fracture of 12.


TREATMENT DONE: Partial extraction with socket shield preparation & implant placement done with 12.



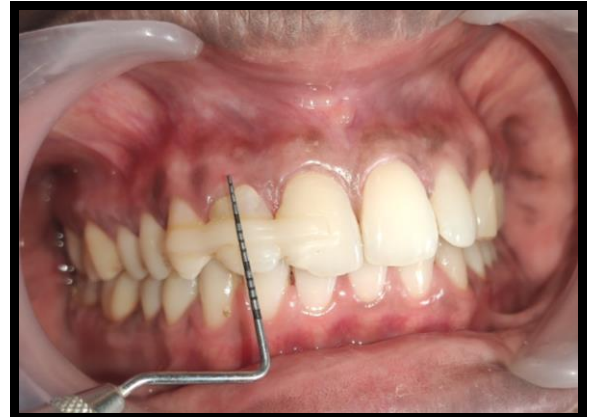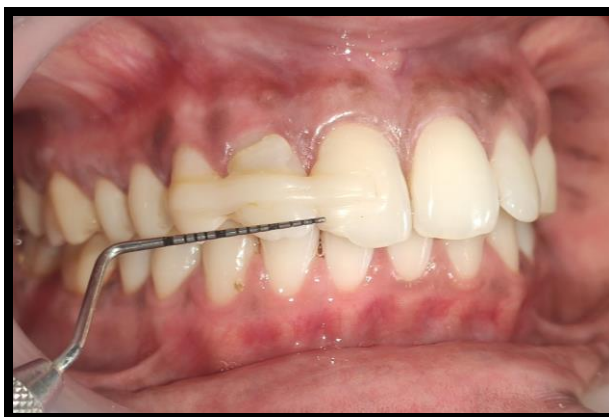**PREOPERATIVE RVG**



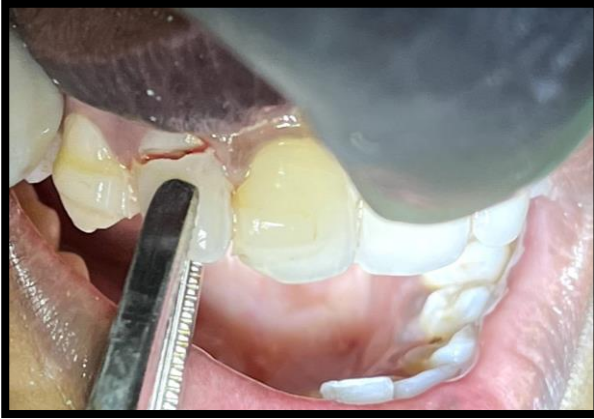**PREOPERATIVE ROOT MEASUREMENT**



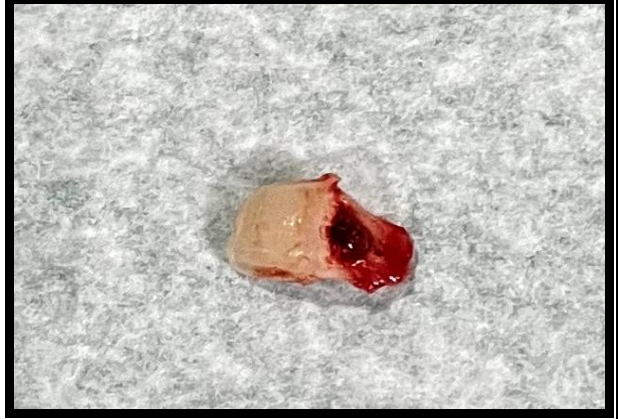**PREOPERATIVE CBCT**



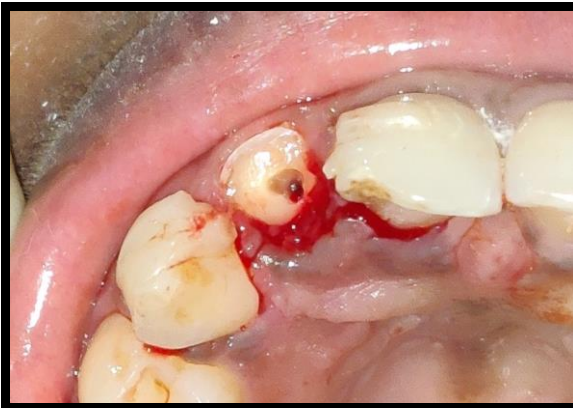
**PREOPERATIVE INTRAORAL MEASUREMENTS**



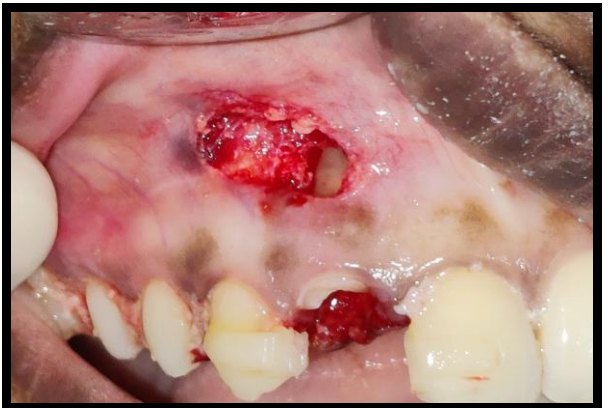
**REMOVAL OF SPLINTED TOOTH**



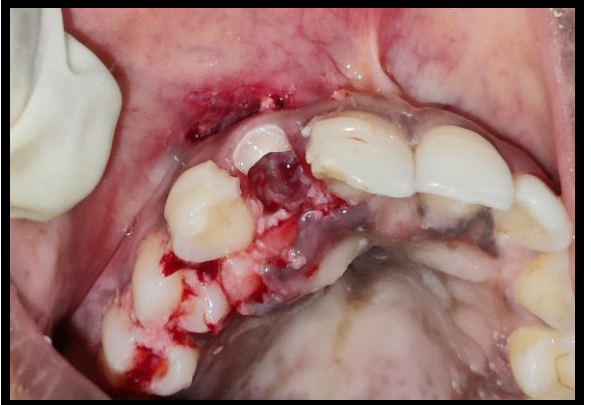
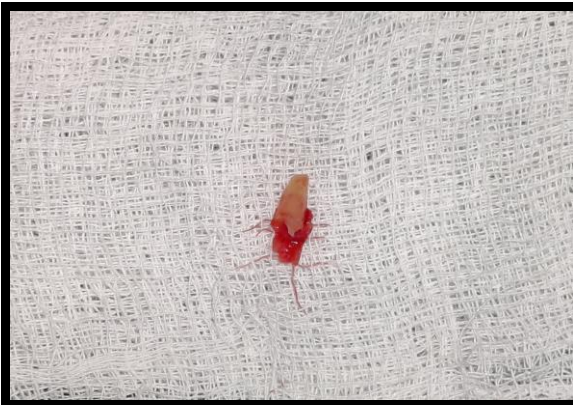**NATURAL PONTIC**



**SULCULAR INCISION**

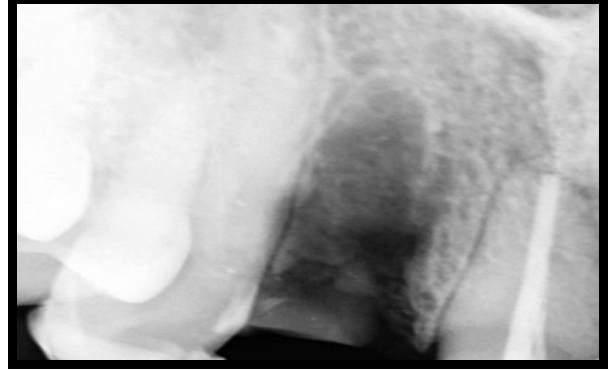
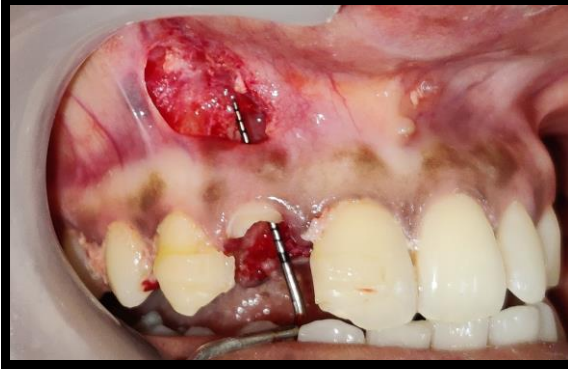
**SPLITTING OF ROOT THROUGH  
ROOT CANAL**



**PARTIAL EXTRACTION DONE.**

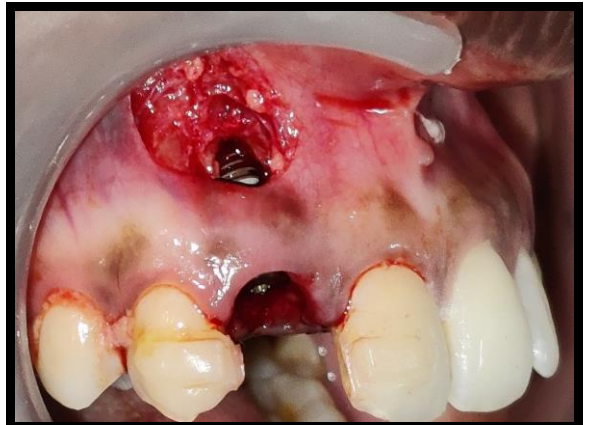




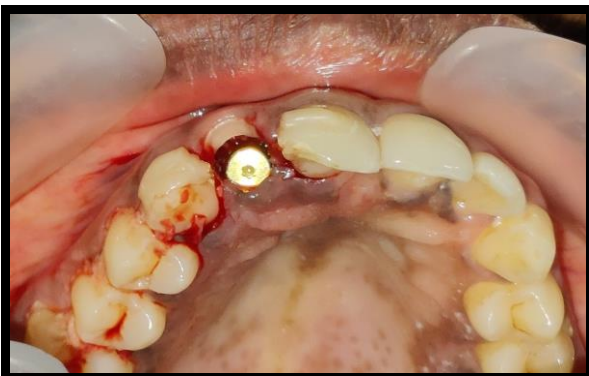
**SOCKET SHIELD PREPARATION.**



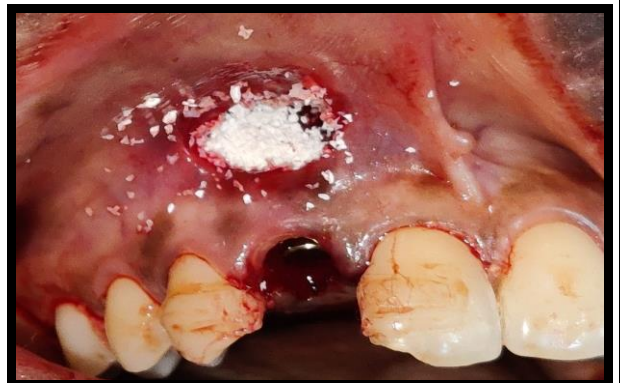**IMPLANT SIZE 3.5X13 SELECTED**



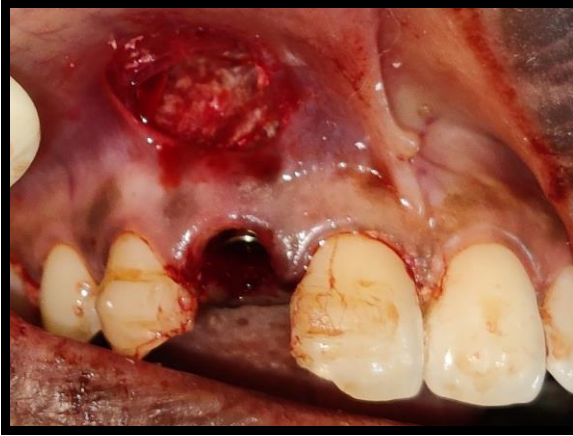**IMPLANT PLACEMENT**



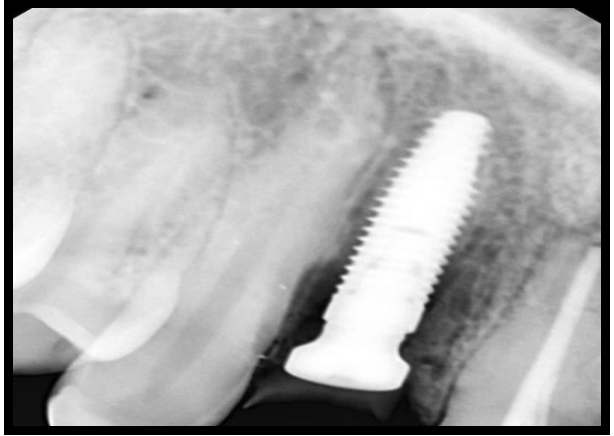**HEALING ABUTMENT PLACEMENT**



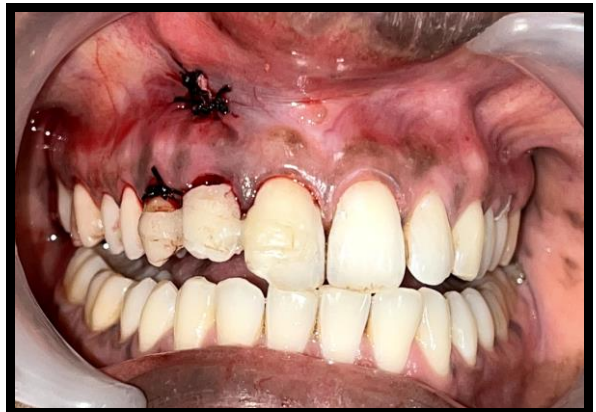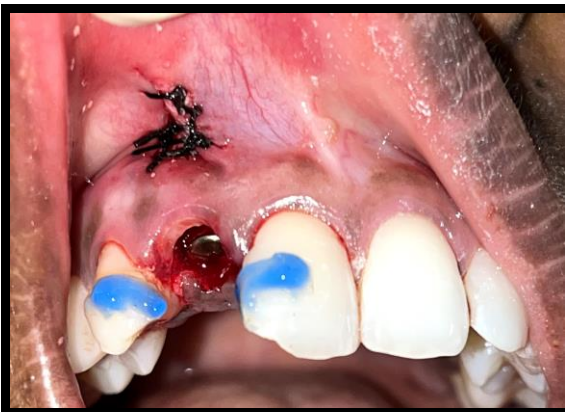**BONE GRAFT PLACEMENT**



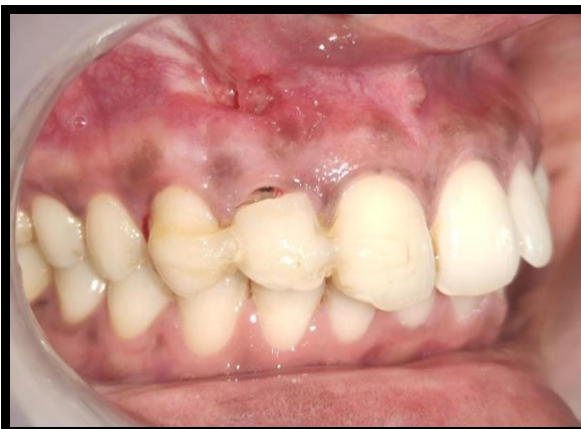**STABILIZATION OF GTR  
MEMBRANE**



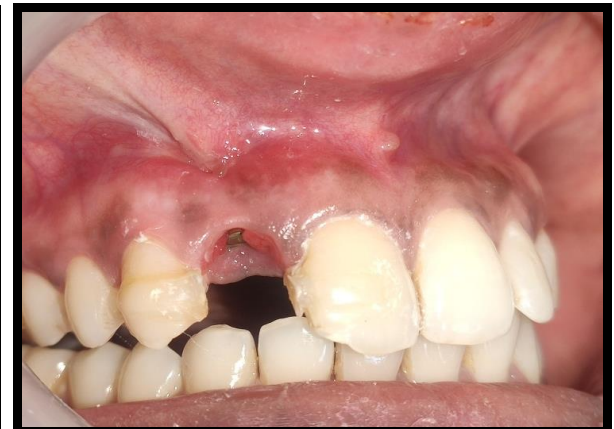**POST OPERATIVE RVG**



**SPLINING OF NATURAL PONTIC & SUTURE PLACEMENT**



**15 DAYS FOLLOW UP**



**1MONTH FOLLOW UP**