

## **PERIPHERAL OSSIFYING FIBROMA**

**PATIENT NAME: Ms. G. U**

**AGE: 12 years**

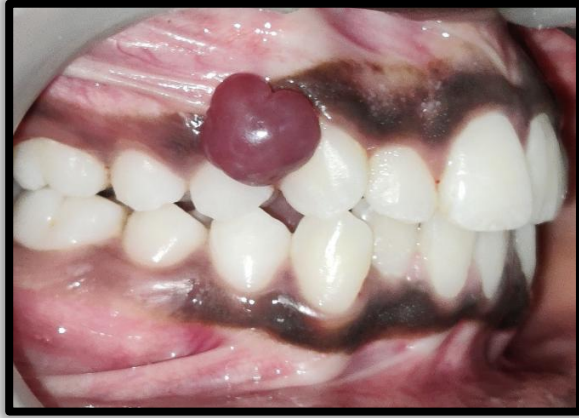**GENDER: F**

**OPD NO: 238440**

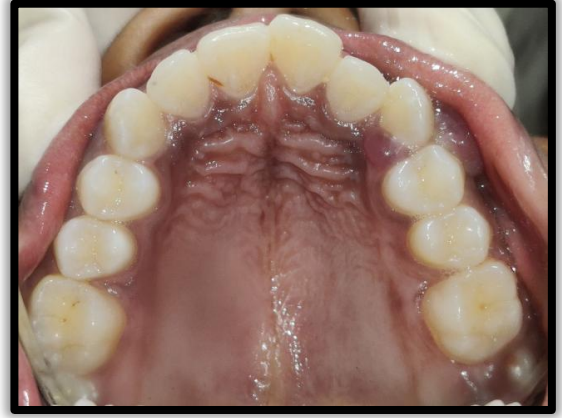**DIAGNOSIS: Localised non-plaque induced gingival reactive process in the form of peripheral ossifying fibroma wrt #13 and #14**

**TREATMENT DONE: Excision of peripheral ossifying fibroma wrt #13 and #14**

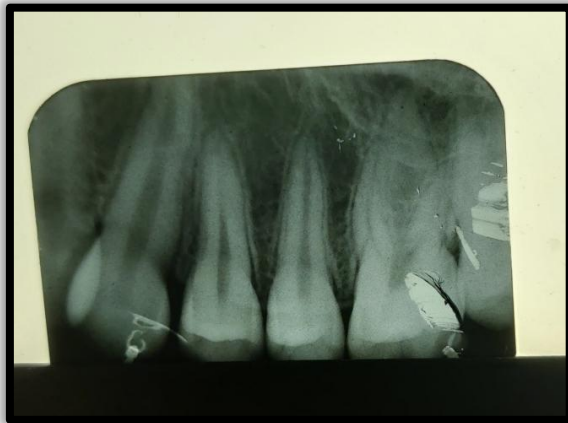
**PERIPHERAL OSSIFYING FIBROMA**



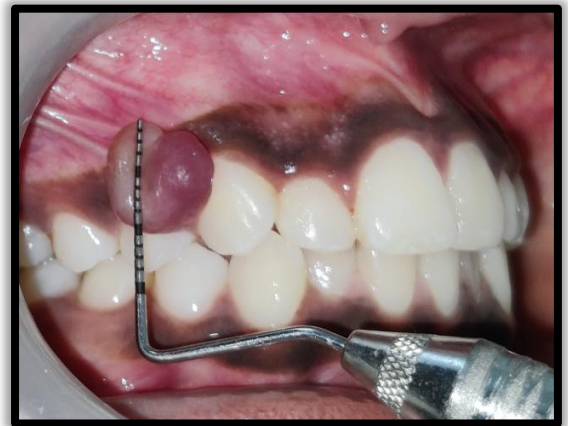**PRE-OPERATIVE VIEW**



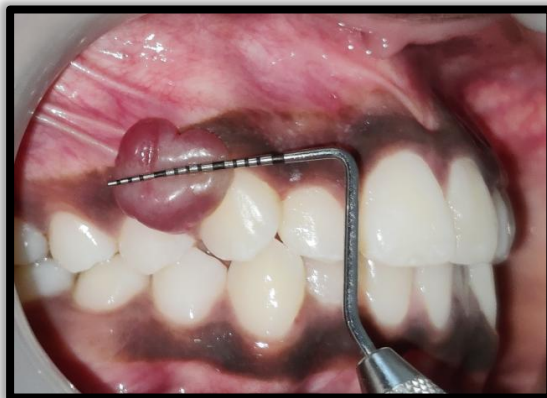**PRE-OPERATIVE MAXILLARY OCCLUSAL VIEW**



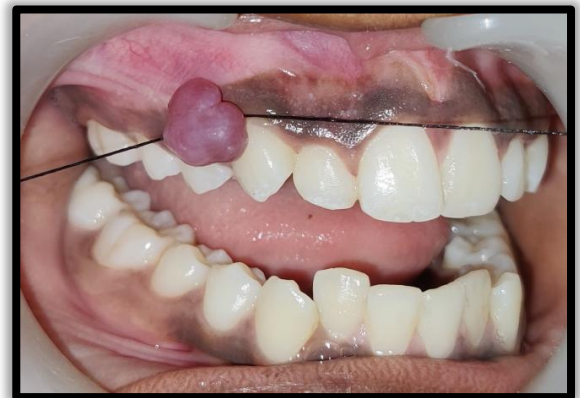**IOPA WRT # 13, #14, #15, AND #16**



**HEIGHT OF LESION = 9 MM**

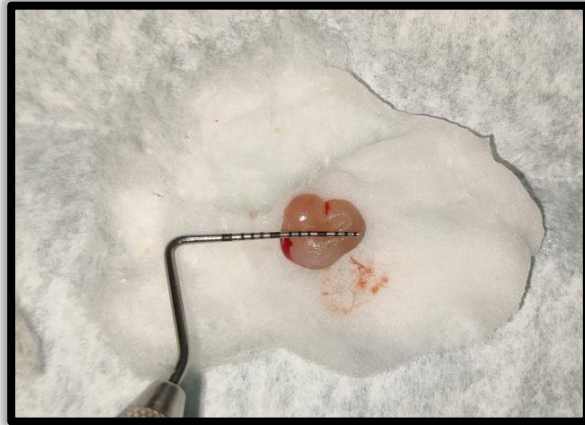


**WIDTH OF LESION = 10 MM**

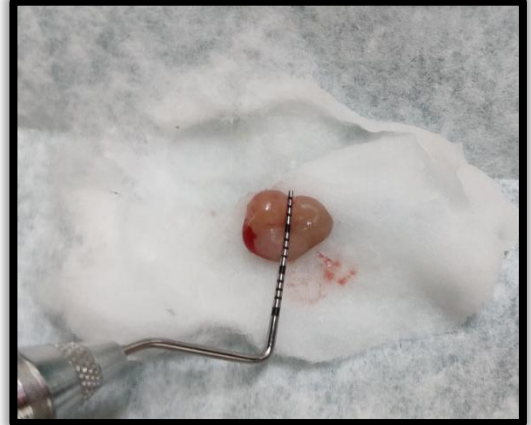

**LESION STABILIZED WITH SUTURE**

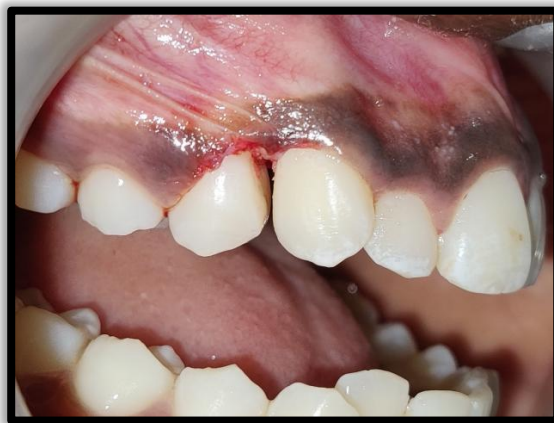PERIPHERAL OSSIFYING FIBROMA



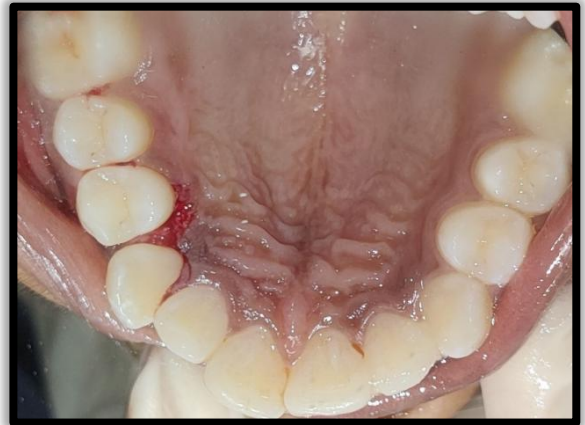**WIDTH AFTER EXCISION OF  
LESION = 8 MM**



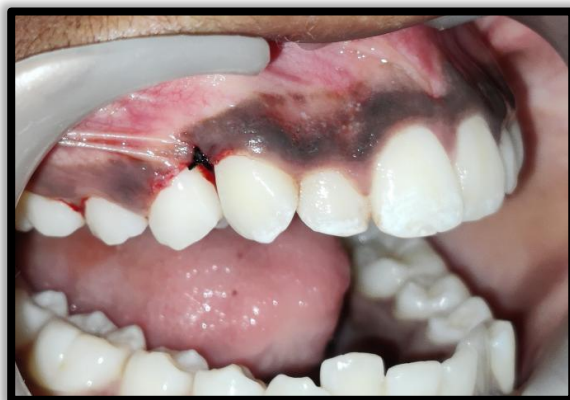**HEIGHT AFTER EXCISION OF  
LESION = 8 MM**



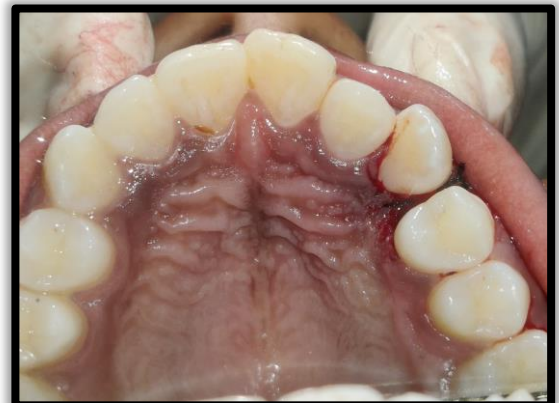**CLINICAL VIEW IMMEDIATELY  
AFTER LESION EXCISION**



**PALATAL VIEW  
IMMEDIATELY AFTER LESION  
EXCISION**

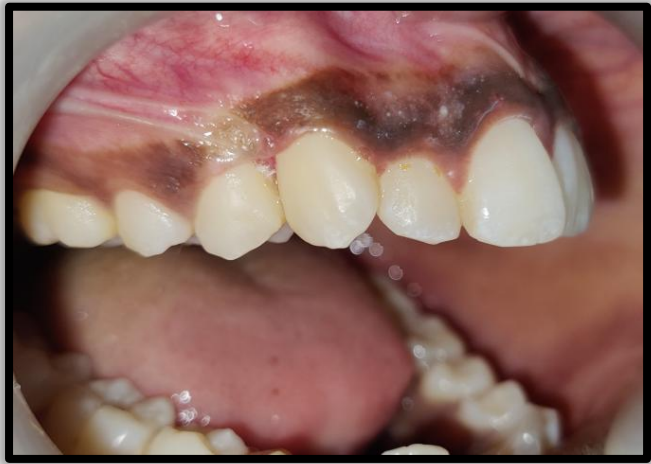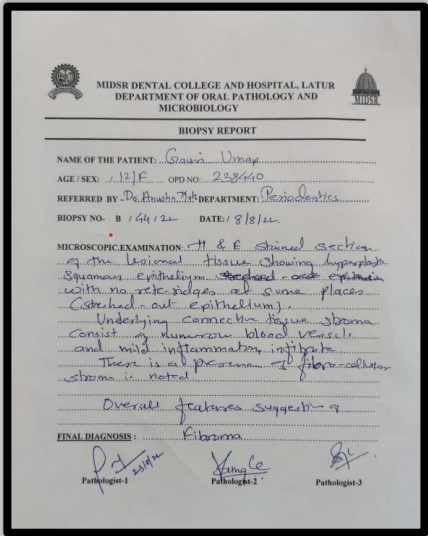


**SUTURE PLACED**



**PALATEL VIEW OF SUTUTRE  
PLACED**

PERIPHERAL OSSIFYING FIBROMA



**BIOPSY REPORT**

**15 DAYS FOLLOW UP**