

REGENERATIVE FLAP SURGERY WITH 16

PATIENT NAME: Miss. A. L.

AGE: 23

GENDER: F

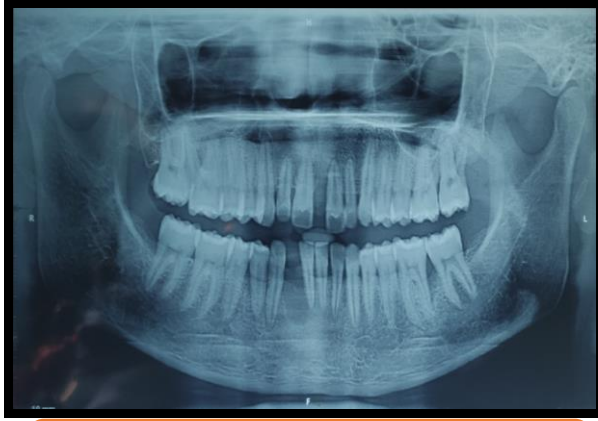OPD NO: 207066

DIAGNOSIS: Generalized periodontitis, Stage III; Grade B; currently unstable; with no risk factor; Mucogingival deformity and condition with generalized gingival recession.

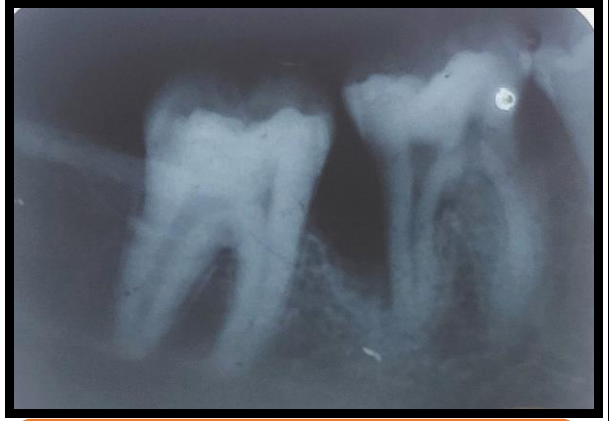Other diagnosis: Intrabony defect with 16.

TREATMENT DONE: Kirkland flap surgery with DFDBA & GTR membrane placement with 16.

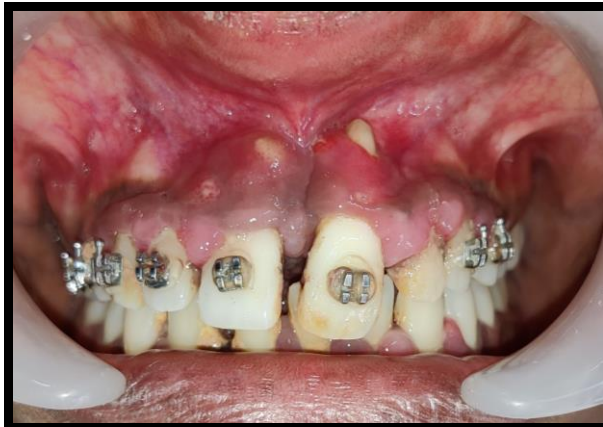.



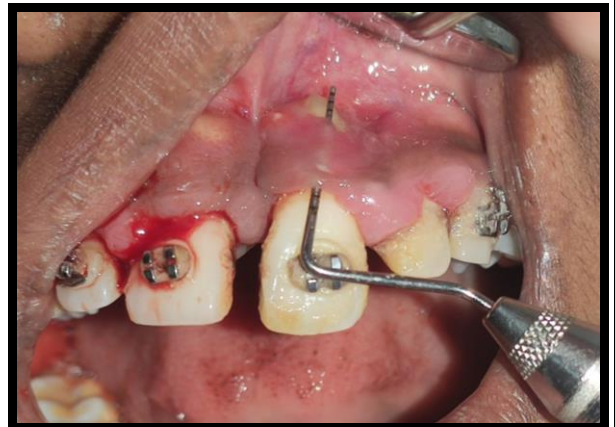PREOPERATIVE OPG



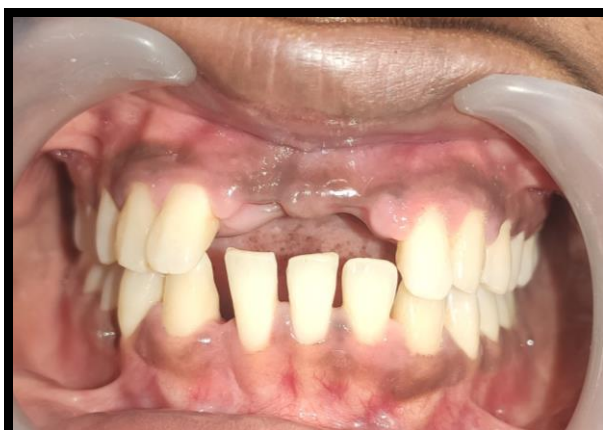PREOPERATIVE RVG



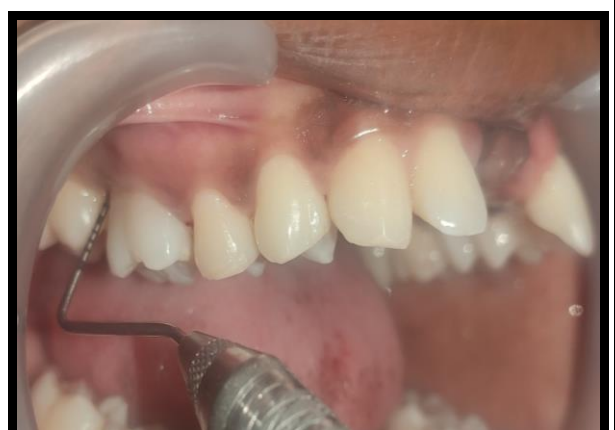**PREOPERATIVE FRONTAL
VIEW**



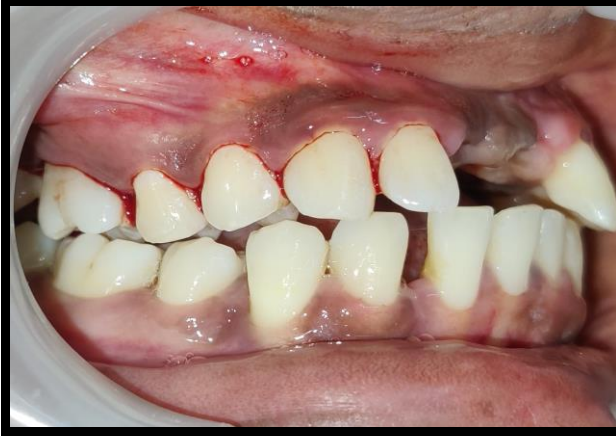SOFT TISSUE DEHISCENCE



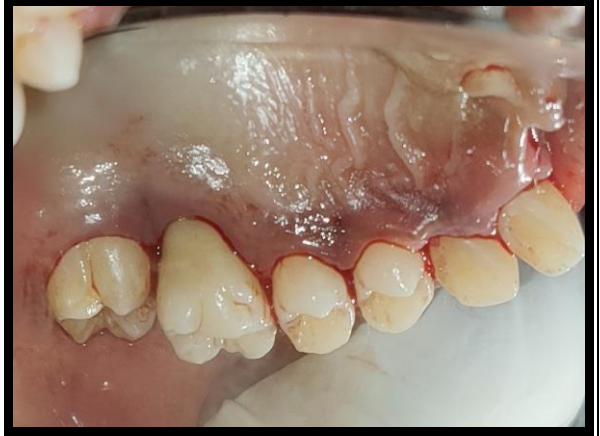**FRONTAL VIEW AFTER
EMERGENCY PHASE**



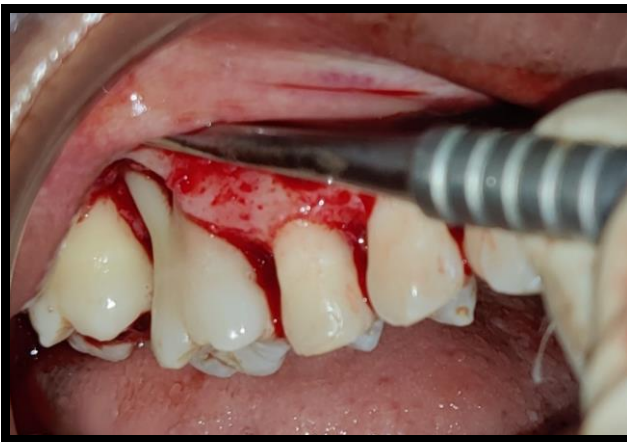**PREOPERATIVE RIGHT
MAXILLARY VIEW**



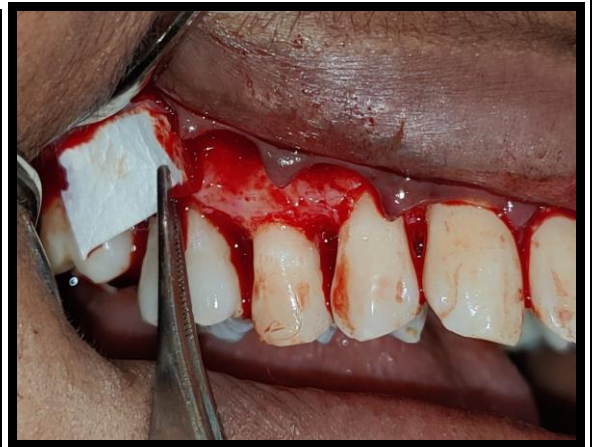BUCCAL SULCULAR INCISION



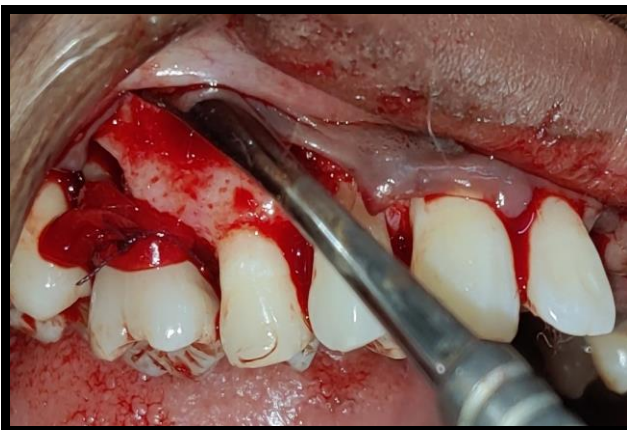
PALATAL SULCULAR INCISION



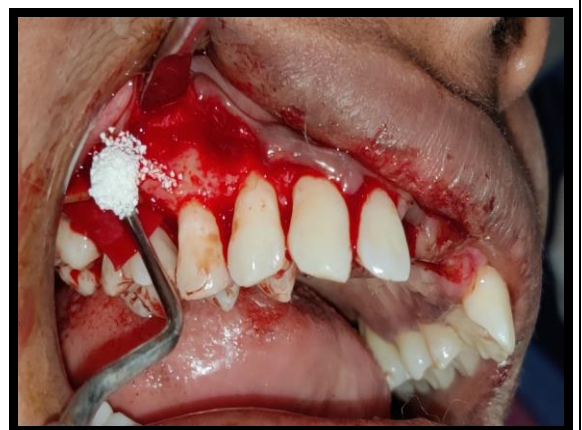**FLAP REFLECTION AND
LOCATE INTRABONY DEFECT**



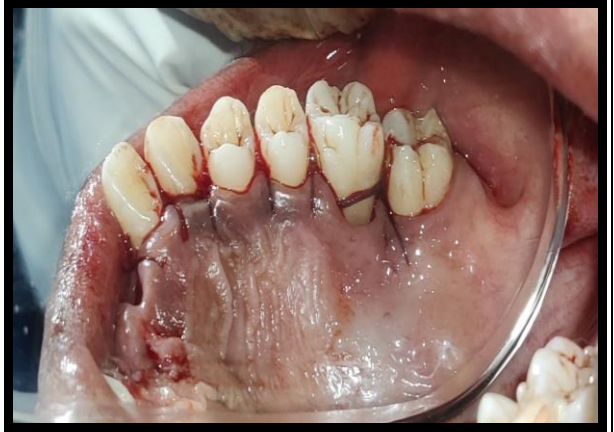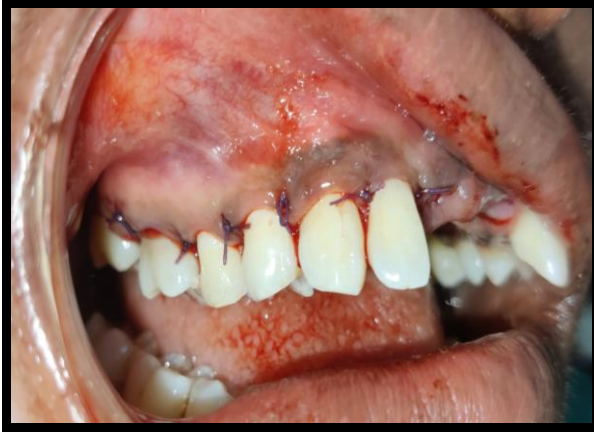**GTR MEMBRANE
PLACEMENT WITH #16**



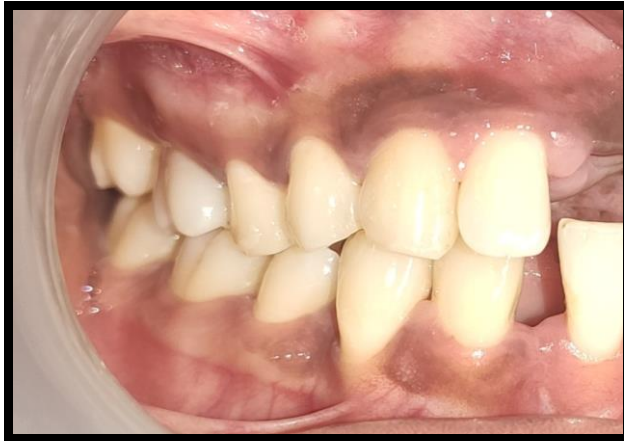**GTR MEMBRANE
STABILIZATION**



**BONE GRAFT PLACEMENT
WITH #16**



SUTURE PLACEMENT



15 DAYS FOLLOW UP