

EXTERNAL BEVEL GINGIVECTOMY

PATIENT NAME: Mr. P. K.

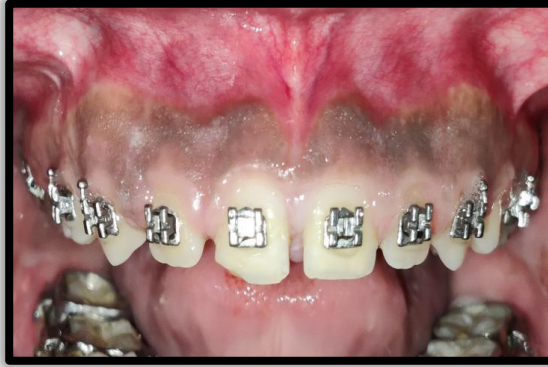AGE: 15 years

GENDER: M

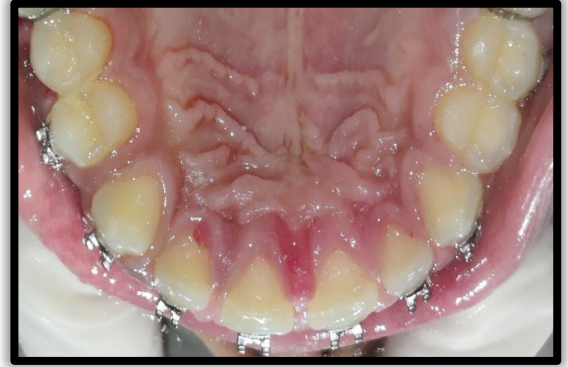OPD NO: 167218

DIAGNOSIS: Dental biofilm induced gingivitis in an intact periodontium with mucogingival deformity and condition with gingival excess with pseudo pocket 31, 32, 33, 41, 42, 43.

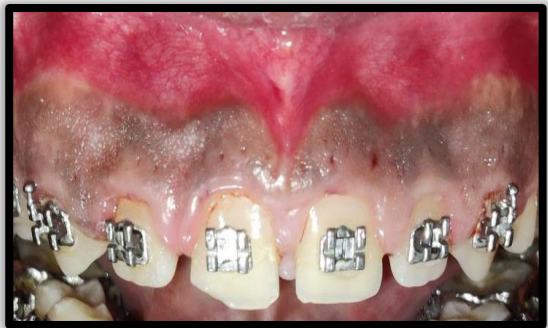TREATMENT DONE: External bevel gingivectomy with Maxillary anterior teeth.



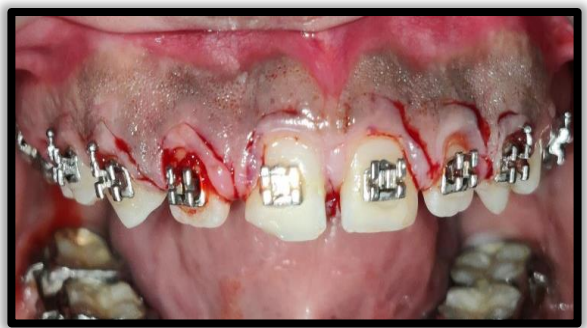FRONTAL VIEW



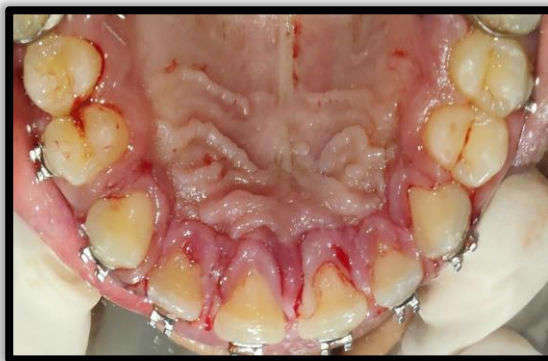PALATAL VIEW



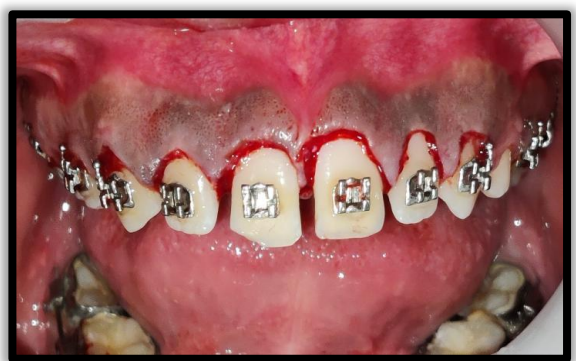**BLEEDING POINTS MARKED IN
MAXILLARY ANTERIOR
GINGIVA**



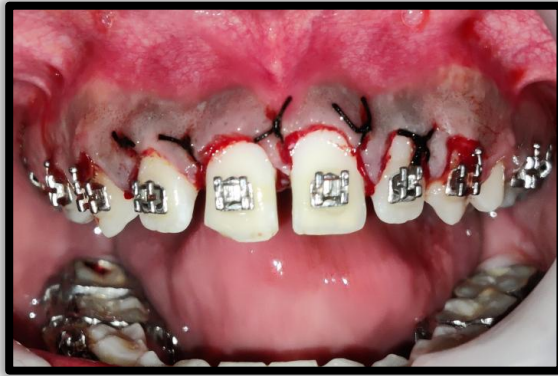**EXTRNAL BEVEL INCISION
GIVEN WITH BLADE TOWARDS
TEETH**



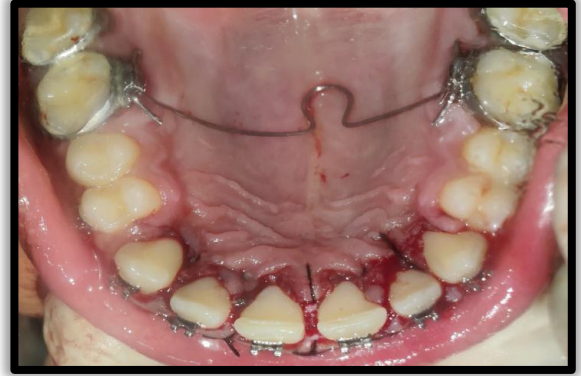
**EXTRNAL BEVEL INCISION
GIVEN WITH PALATEL VIEW**



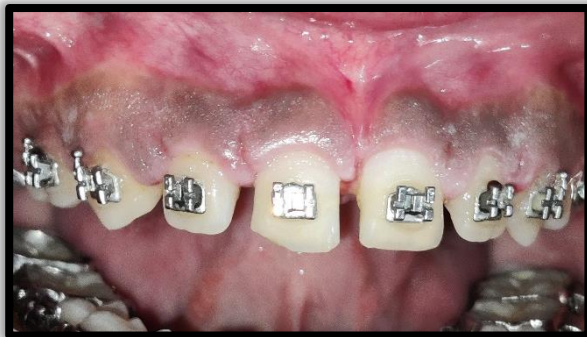GINGIVOPLASTY DONE



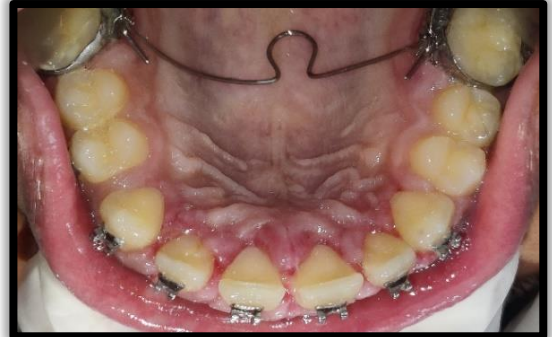SUTURE PLACED



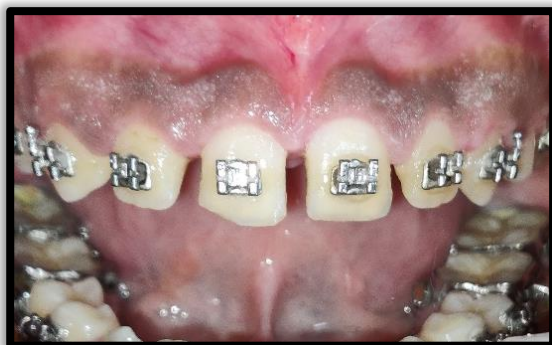**SUTURE PLACED WITH
PALATAL VIEW**



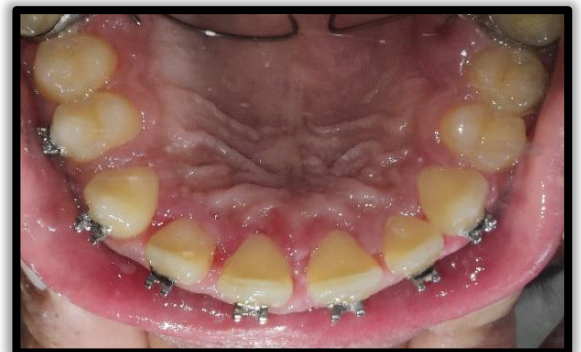**7 DAYS AFTER SUTURE
REMOVAL**



**7 DAYS AFTER SUTURE
REMOVAL PALATAL VIEW**



1 MONTH FOLLOW UP



**1 MONTH FOLLOW UP
PALATAL VIEW**