

**RESIDUAL CYST EXCISION WITH
IMMEDIATE IMPLANT WRT 11**

PATIENT NAME: Mr. P. R.

AGE: 22 years

GENDER: M

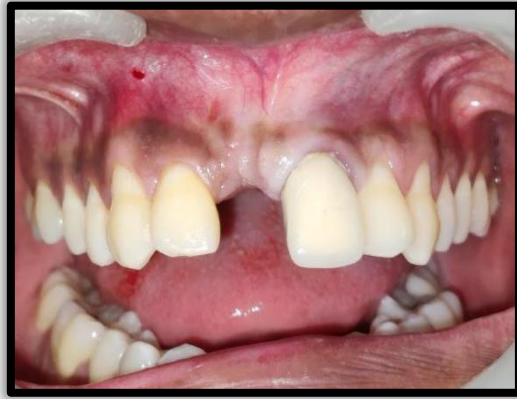OPD NO: 248855

DIAGNOSIS: Dental biofilm induced generalised gingivitis with Intact periodontium with edentulous space w r t 11.

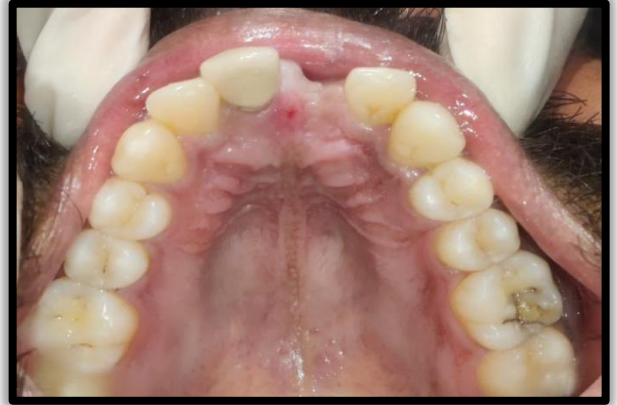Other diagnosis: Residual cyst wrt 11.

TREATMENT DONE: Residual cyst excision with immediate implant placement done wrt 11.

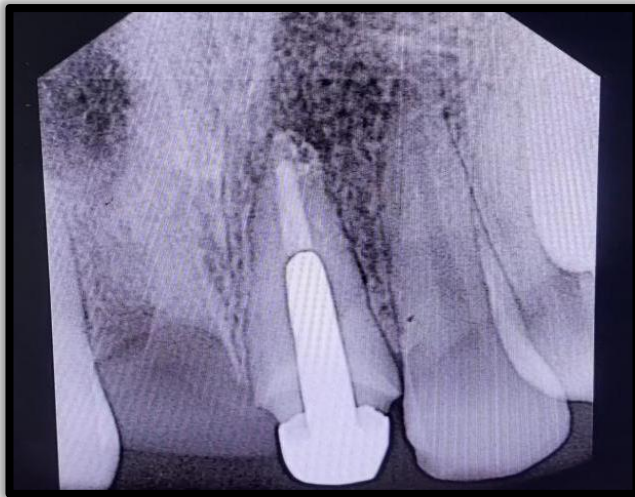
Bony cyst removal with immediate implant placement



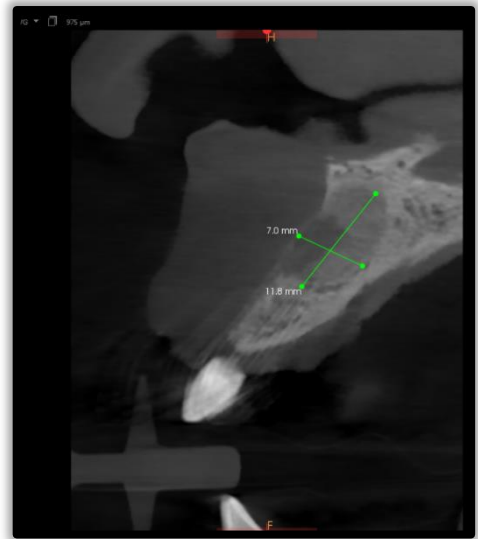
**PRE-OPERATIVE FRONTAL
VIEW WRT #11**



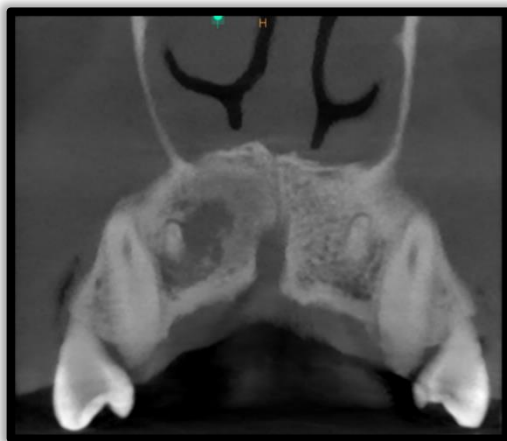
**PRE-OPERATIVE OCCLUSAL
VIEW WRT #11**



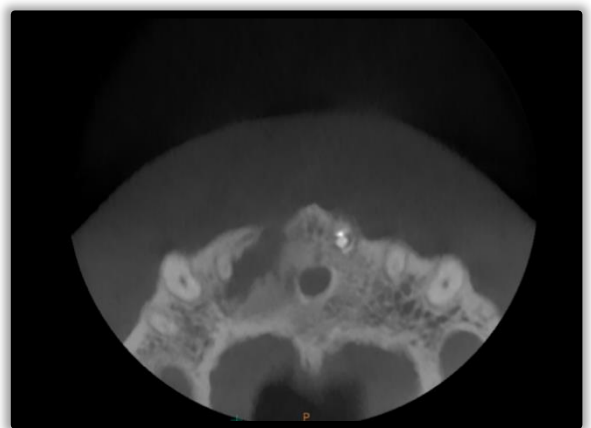
PRE-OPERATIVE RVG



**CBCT SHOWING SAGITTAL
VIEW OF CYST OF HEIGHT
11.8 MM AND WIDTH OF 7.0
MM**

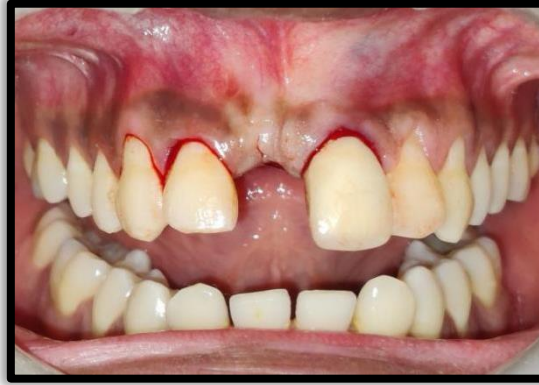

**CORONAL VIEW OF CBCT
SHOWING CYST**

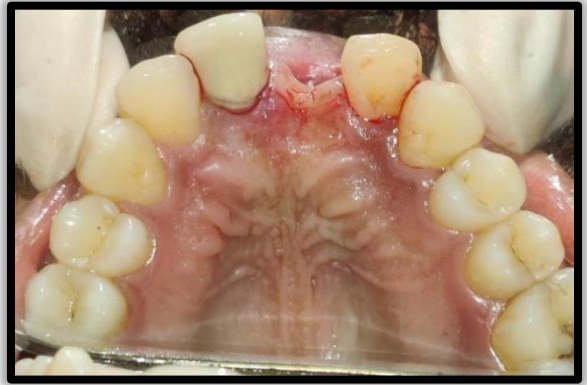

**AXIAL VIEW OF CBCT
SHOWING CYST**

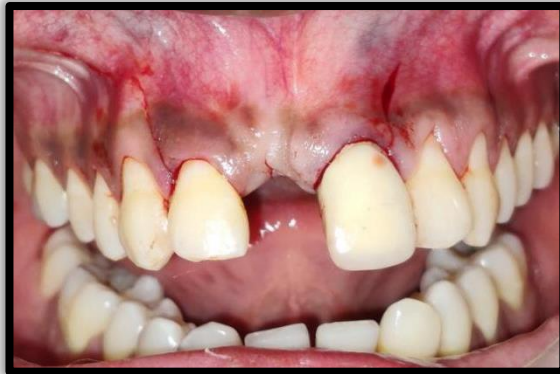Bony cyst removal with immediate implant placement



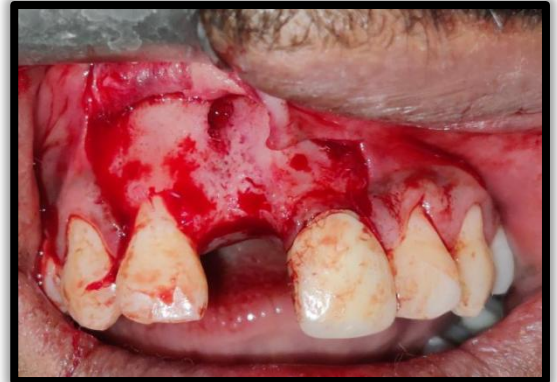
**INTRACREVICULAR INCISION
GIVEN WITH #12 BLADE WRT
#12. #21**



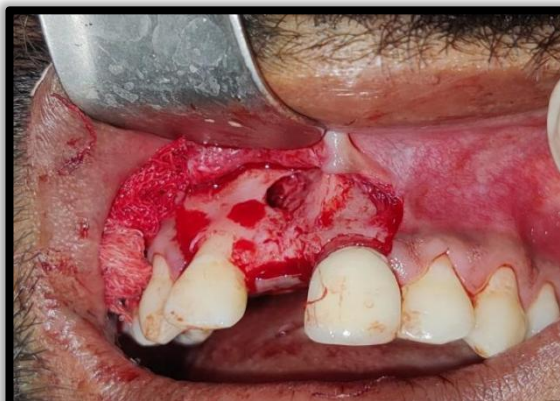**HORIZONTAL PARACRESTAL
INCISION GIVEN OVER
EDENTULOUS SITE**



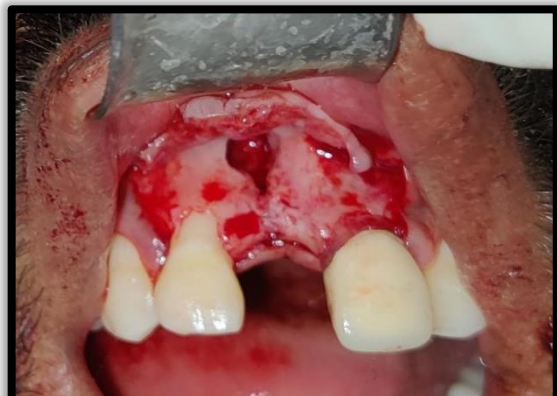**TWO VERTICAL INCISION
GIVEN**



FLAP REFLECTED

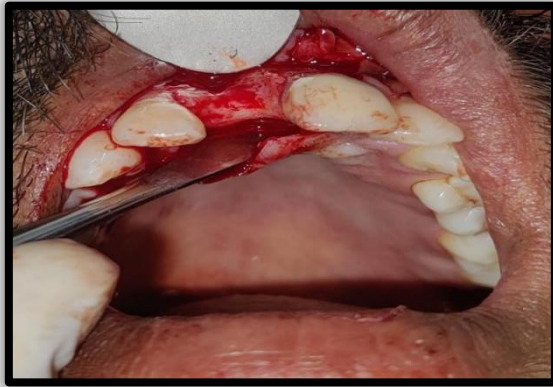


**RESIDUAL BONY CYST
VISULIZED**

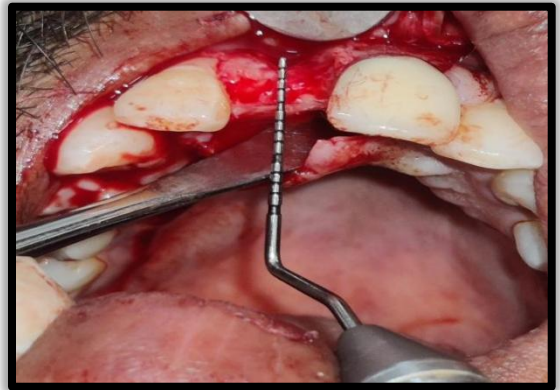


CYST DEBRIDEMENT DONE

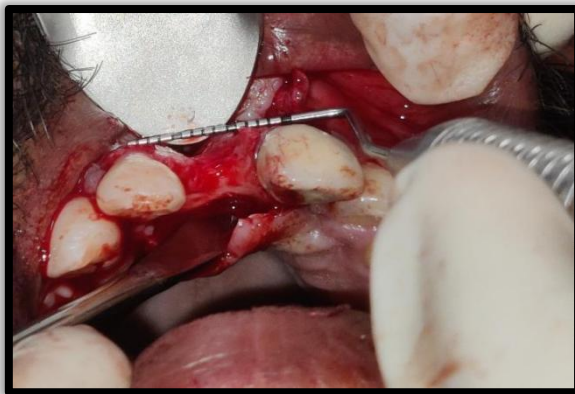
Bony cyst removal with immediate implant placement



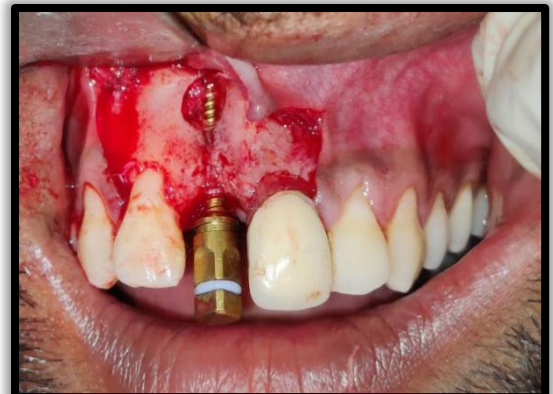**OCCLUSAL VIEW OF
EDENTULOUS RIDGE**



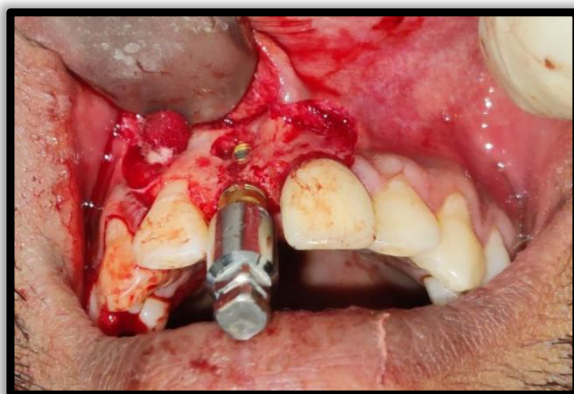
**BUCCO-PALATAL RIDGE
WIDTH OF 2MM**



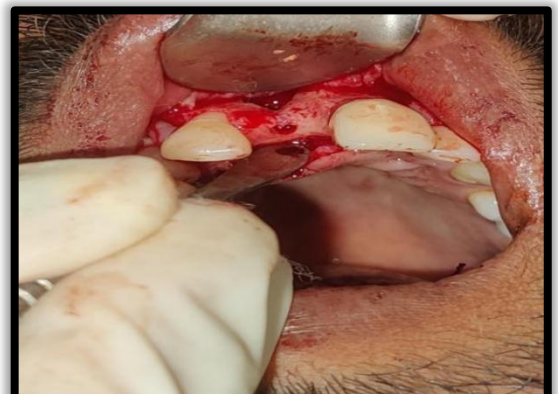**MESIO-DISTAL DISTANCE OF
7MM**



EXPANDER OF SIZE 2.3 MM




EXPANDER OF SIZE 3.1 MM

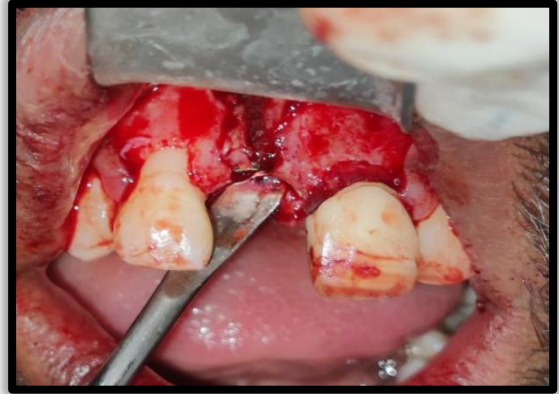


OSTEOTOMY SITE PREPARED

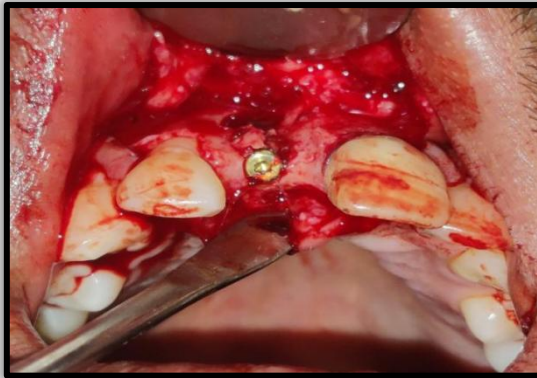
Bony cyst removal with immediate implant placement



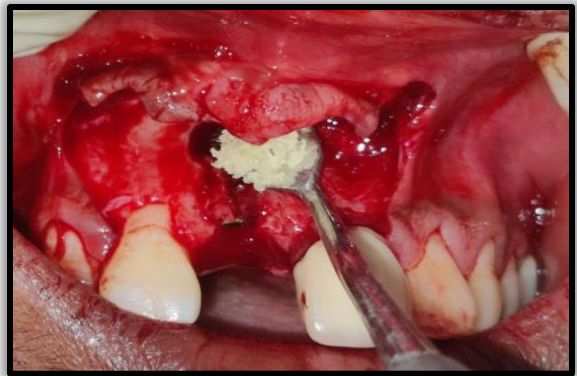
IMPLANT OF SIZE 3.5×13 MM



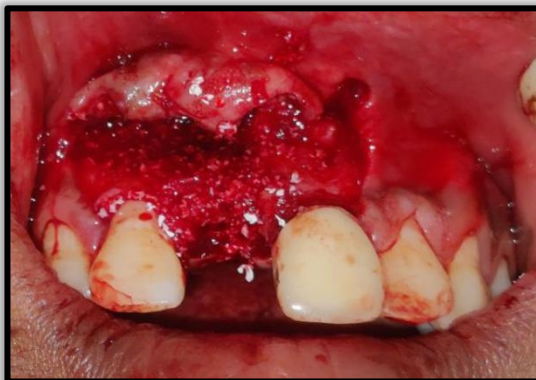**IMPLANT PLACEMENT
WITH THREAD EXPOSED ON
BUCCAL SIDE**



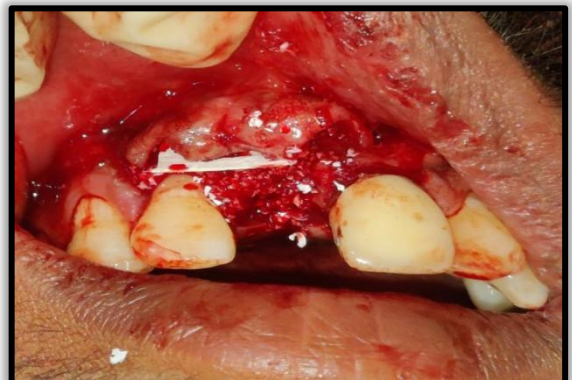
**COVER SCREW PLACED OG
GINGIVAL HEIGHT SIZE OF 2
MM**



**BIO-OSS BONE GRAFT PLACED
OVER CYST AND EXPOSED
THREAD**

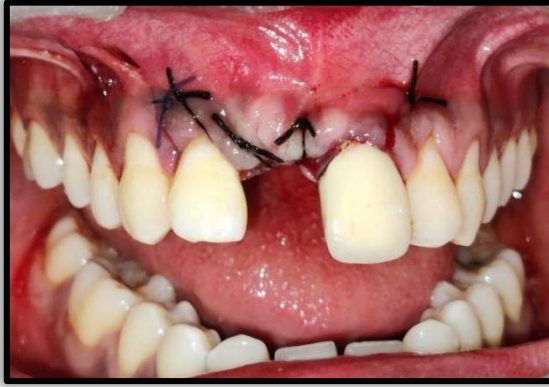

**AFTER BIO-OSS BONE GRAFT
PLACED**

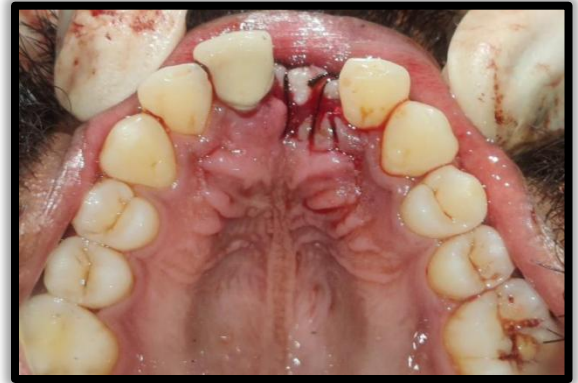

**GUIDED TISSUE
REGENERATIVE MEMBRANE
PLACED**

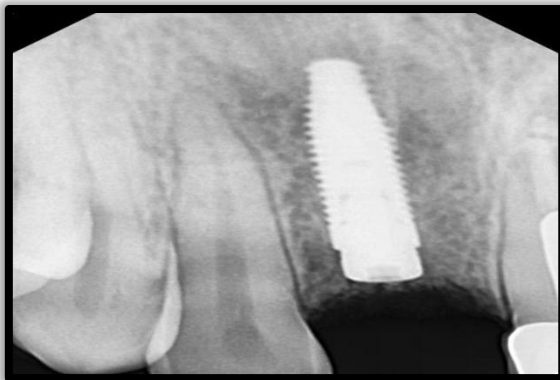
Bony cyst removal with immediate implant placement



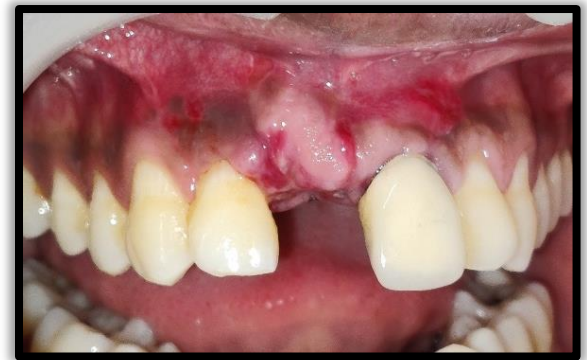**SUTURING DONE WITH 4-0
NONRESORABLE SILK SUTURE**



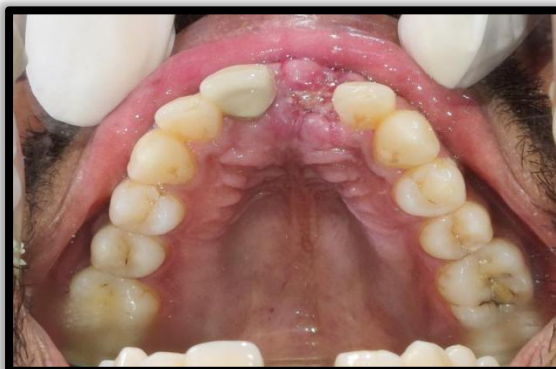SUTURE WITH PALATAL VIEW



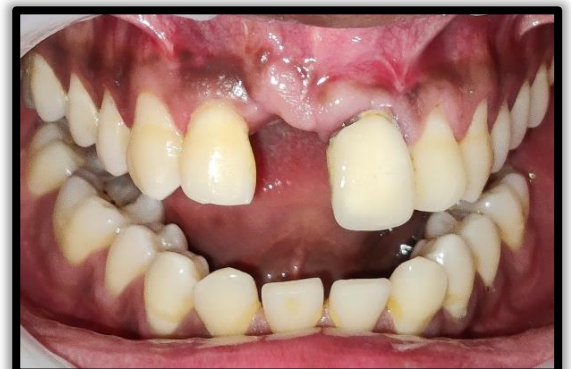IMMEDIATE IMPLANT RVG



**15 DAYS AFTER SUTURE
REMOVAL**

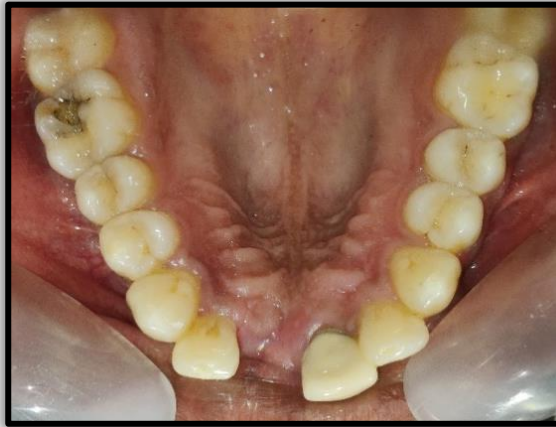

**15 DAYS AFTER SUTURE
REMOVAL PALATAL VIEW**

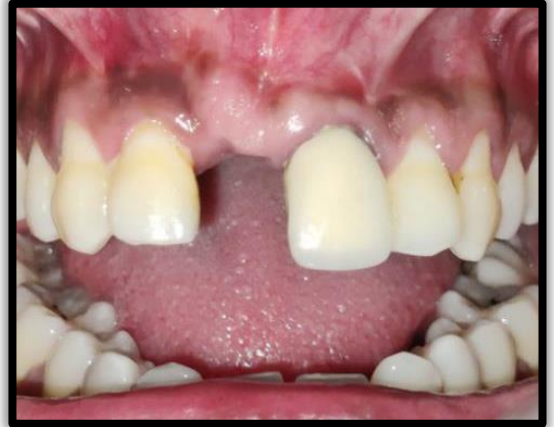

1 MONTH FOLLOW UP

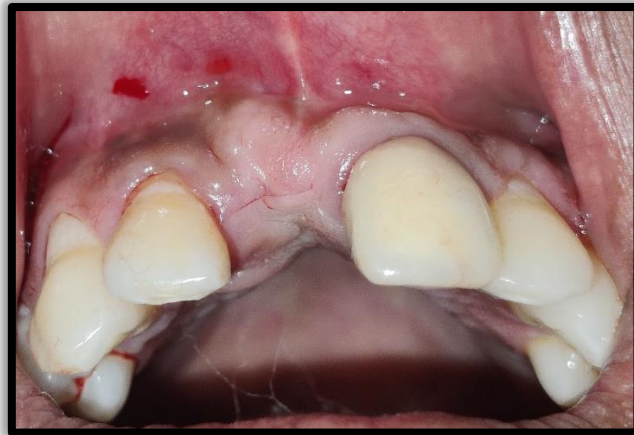Bony cyst removal with immediate implant placement



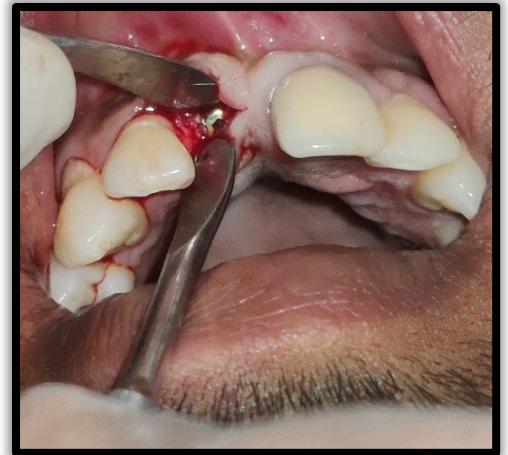1 MONTH FOLLOW UP



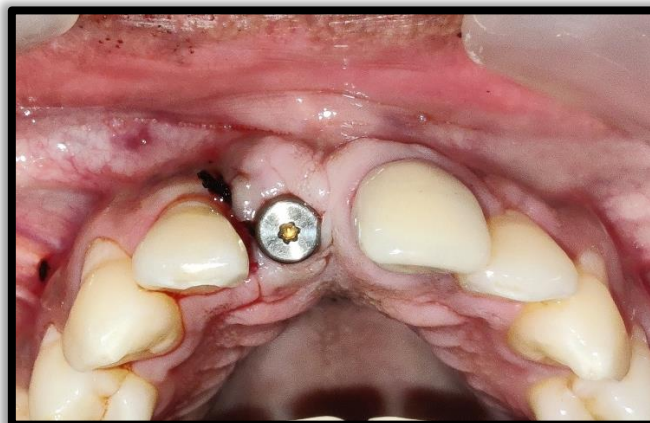
3 MONTH FOLLOW UP



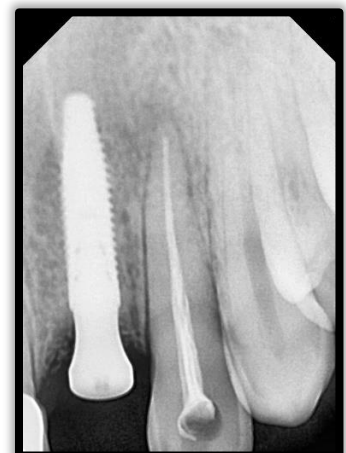PARACRESTAL INCISION
GIVEN



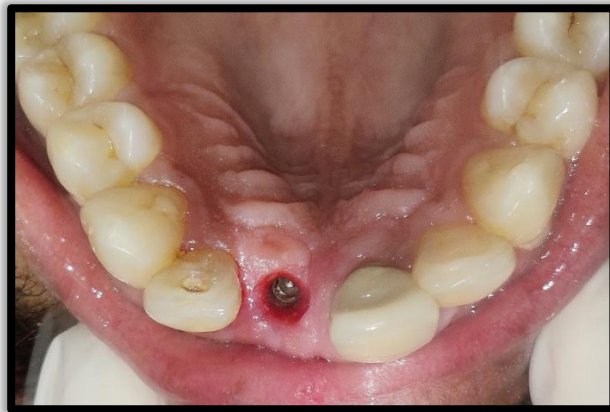FLAP REFLECTION. COVER
SCREW IS SEEN



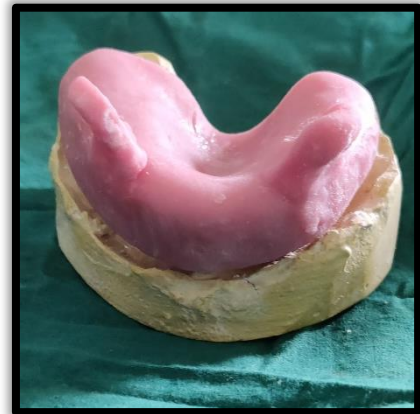HEALING ABUTMENT (4.5
*2.5) PLACED



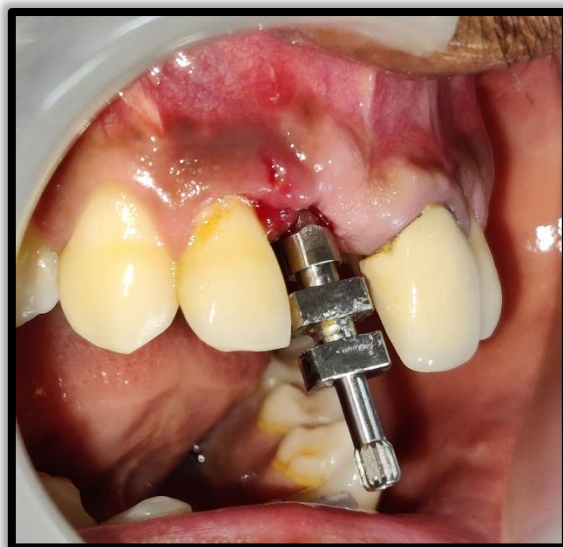
RVG AFTER HEALING
ABUTMENT PLACEMENT



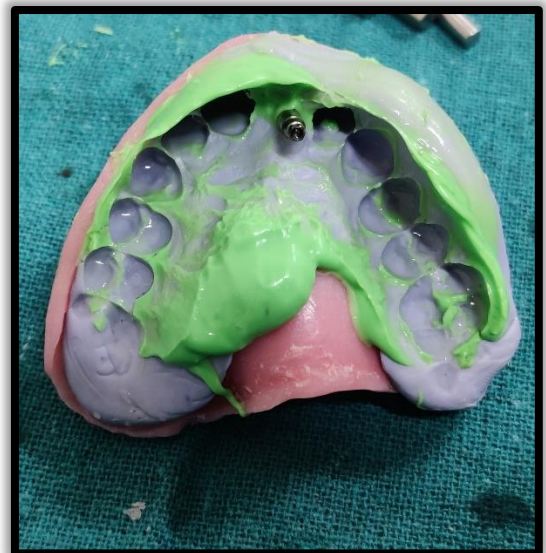**EMERGENCE PROFILE AFTER
REMOVAL OF HEALING
ABUTMENT**



**FABRICATION OF SPECIAL
TRAY**

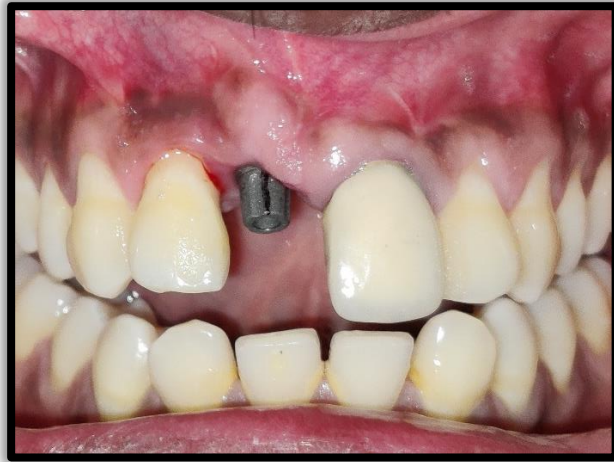

IMPRESSION COPING

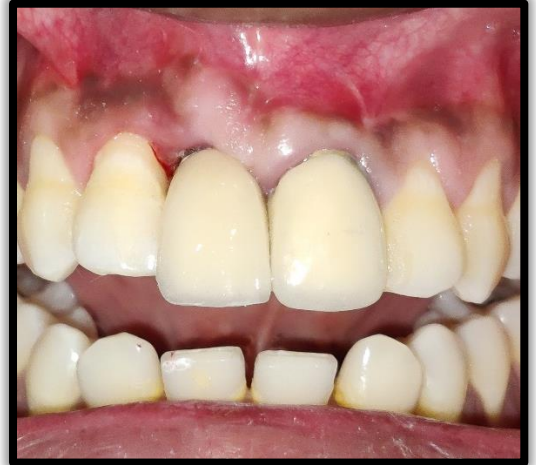

OPEN TRAY IMPRESSION

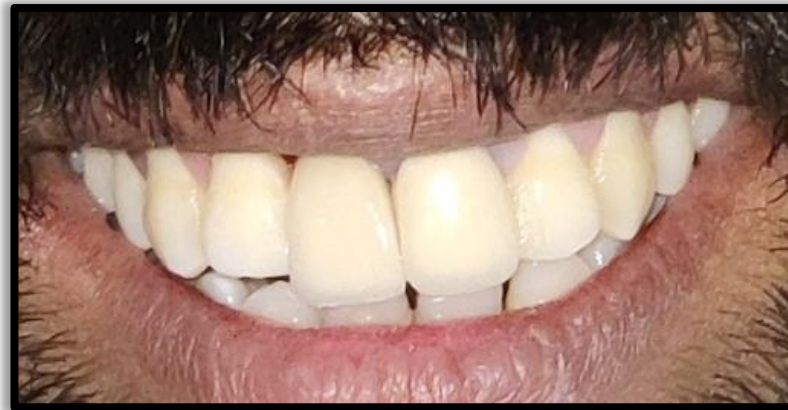Bony cyst removal with immediate implant placement



ABUTMENT OF SIZE 4.5*4*3.5 MM



FINAL PROSTHESIS



PATIENT WITH SMILE