

BILATERAL IMPACTED CANINE EXPOSURE FOR ORTHO TREATMENT

PATIENT NAME: Miss. K. R

AGE: 16

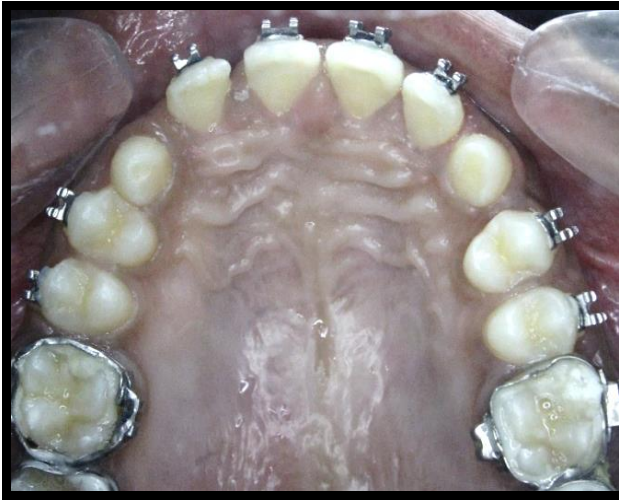GENDER: F

OPD NO: 205062

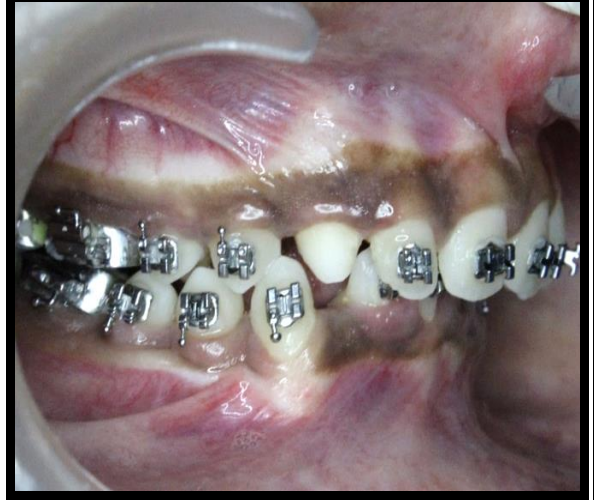DIAGNOSIS: Generalized dental biofilm induced gingivitis in intact periodontium.

OTHER DIAGNOSIS: Impacted teeth with 13,23

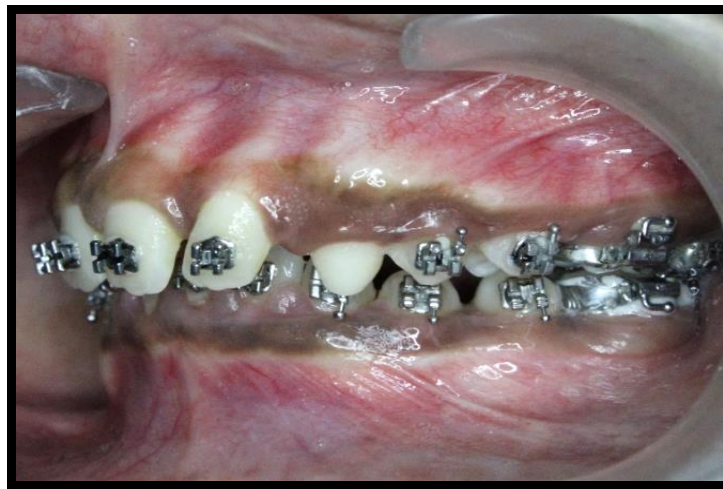TREATMENT DONE: Canine exposure with orthodontic traction.



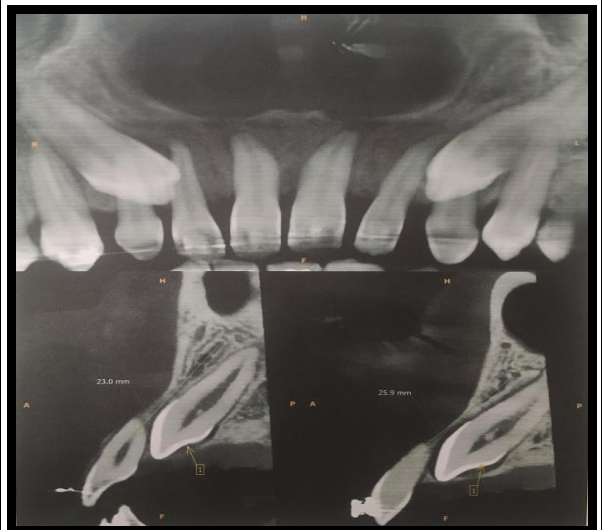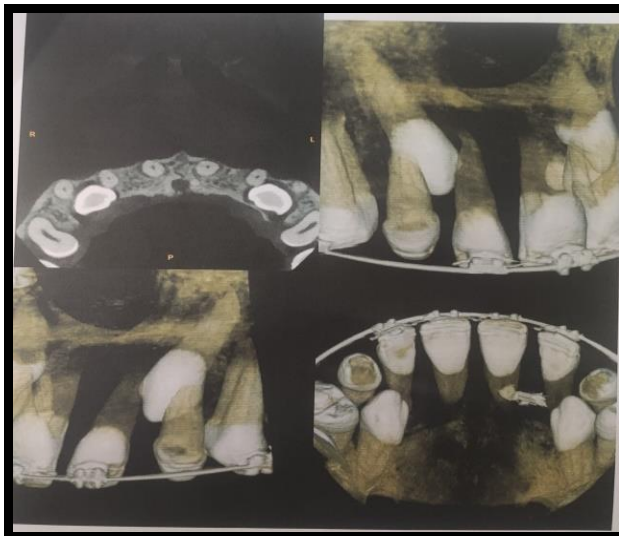MAXILLARY OCCLUSAL VIEW



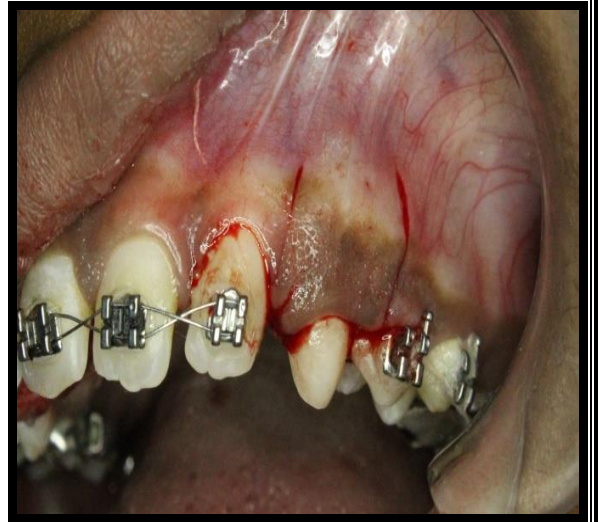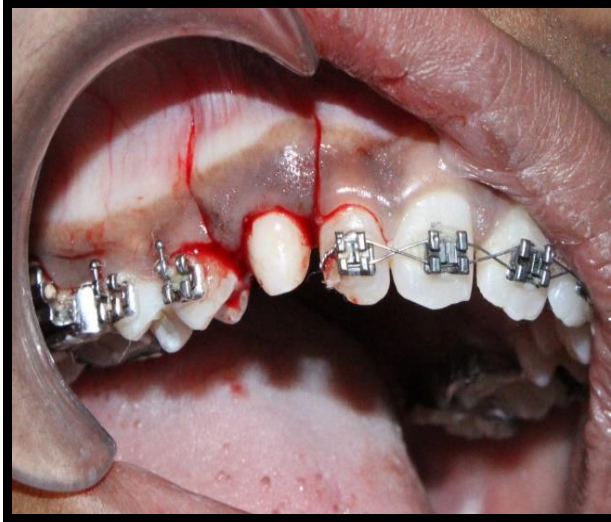**RIGHT LATERAL VIEW WITH
RETAINED DECIDUOUS CANINE**



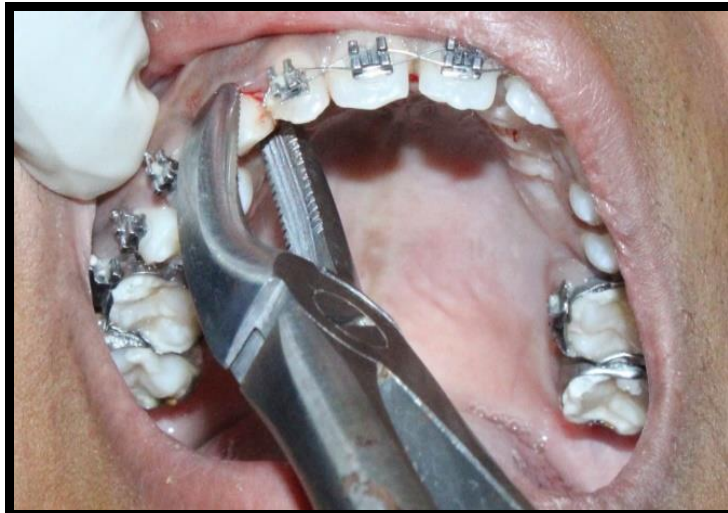**LEFT LATERAL VIEW WITH RETAINED
DECIDUOUS CANINE**



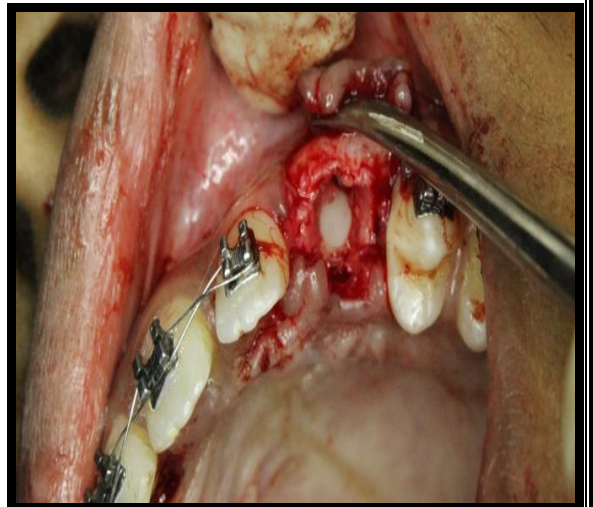
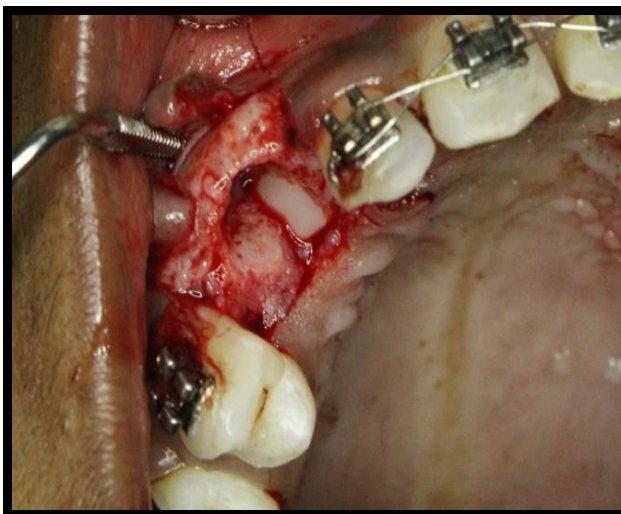
3D VIEW ON CBCT



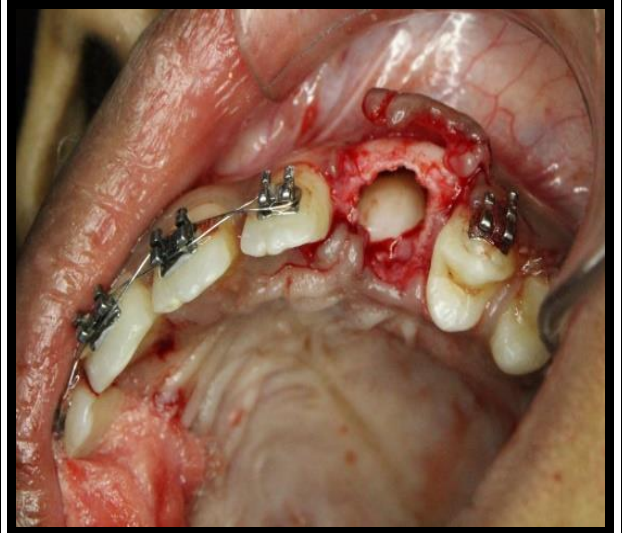
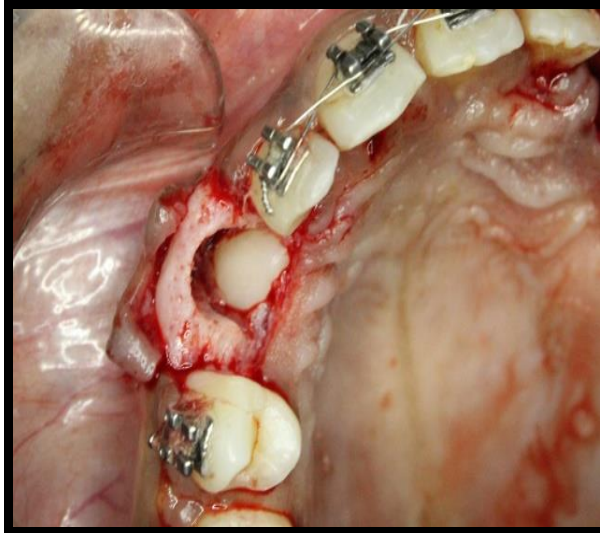
TWO VERTICAL INCISIONS ON EACH DECIDUOUS



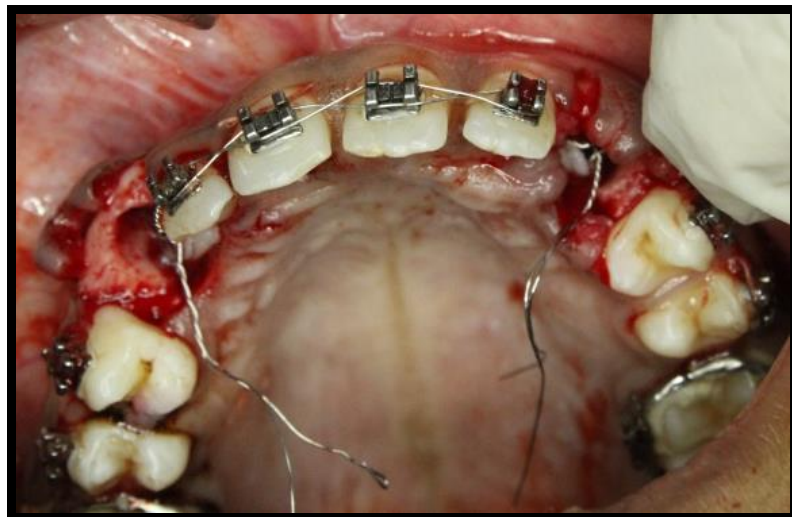
EXTRACTION OF DECIDUOUS CANINE



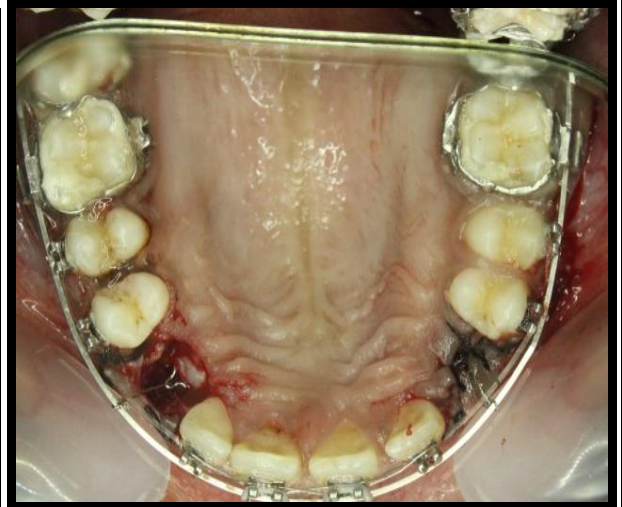
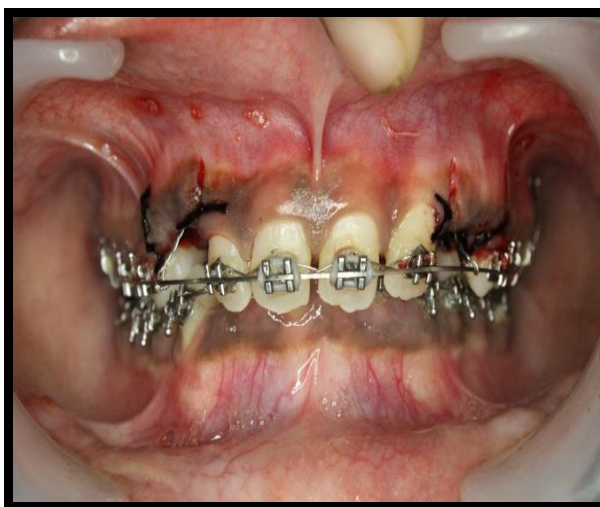OSTECTOMY DONE TO EXPOSE



EXPOSURE OF CANINES



LIGATURE WIRE BONDING TO CANINES



**SIMPLE INTURPTED SUTURE
PLACED**

10 DAYS FOLLOW UP & SUTURE REMOVAL

