

## **APIECTOMY**

**PATIENT NAME:** Mr. A. N.

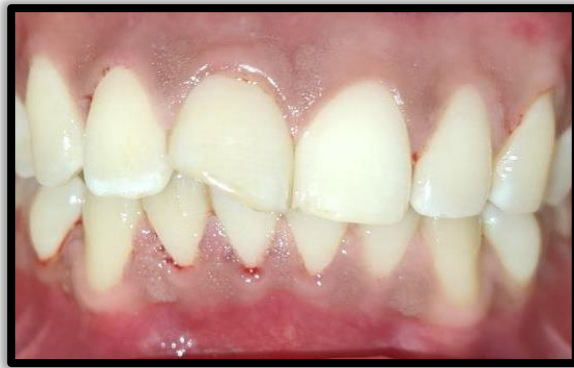**AGE:** 19 years

**GENDER:** M

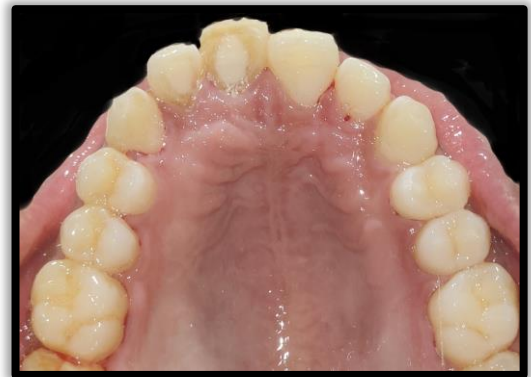**OPD NO:** 208889

**DIAGNOSIS:** Generalised biofilm induced gingivitis with intact periodontium, with endo-perio lesion in non-periodontitis grade 3.

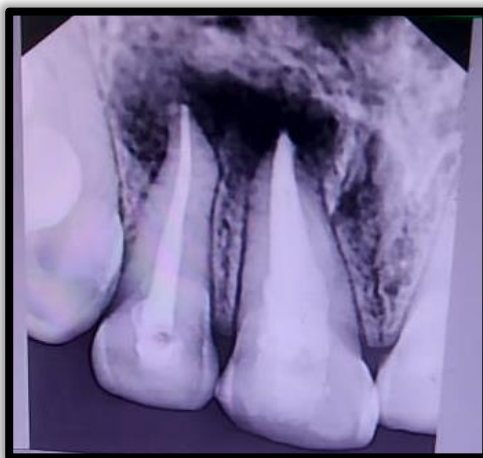
**TREATMENT DONE:** Apiectomy with PRF wrt 11 and 12.



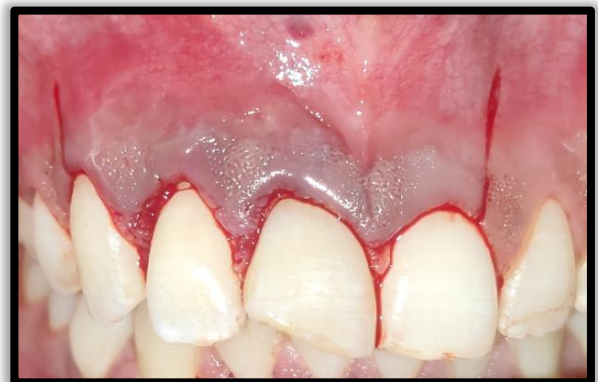**FRONTAL VIEW**



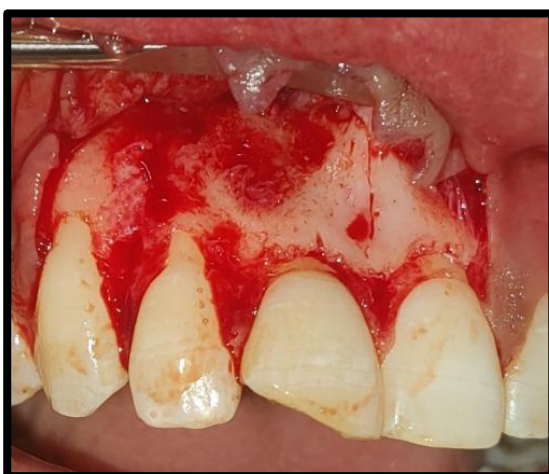**MAXILLARY OCCLUSAL VIEW**



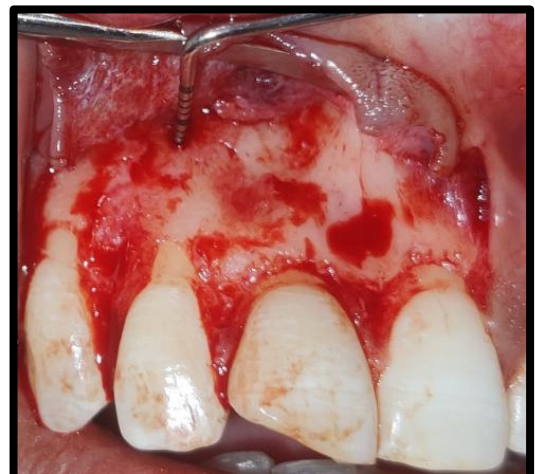**PRE-OPERATIVE IOPA  
WITH RADIOLUCENCY  
SEEN WITH APEX OF # 11  
AND #12**



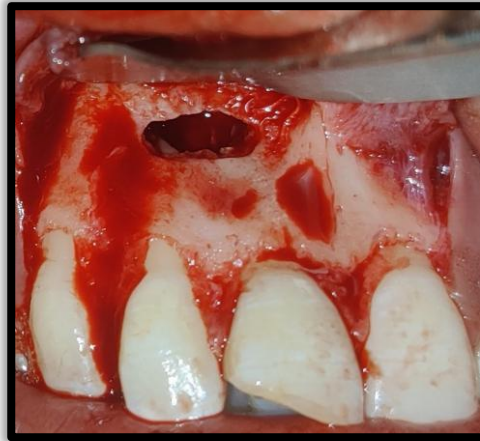
**SULCULAR GIVEN FROM 21 TO 13  
WITH VERTICAL RELEASING  
INCISION ON DISTAL ASPECT WRT  
21 AND 13**



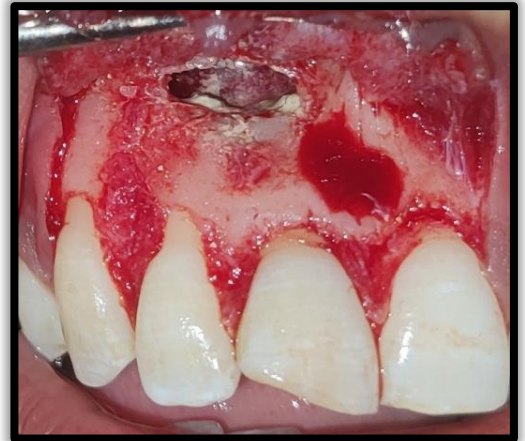**FULL THICKNESS  
MUCOPERISTEUM FLAP  
REFLECTED**



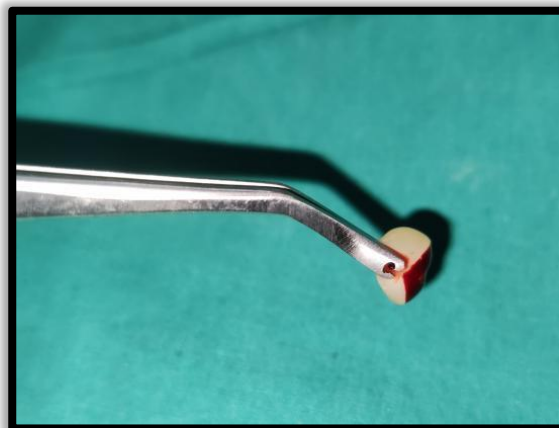**PERIAPICAL CYST  
LOCATED WITH PROBE**



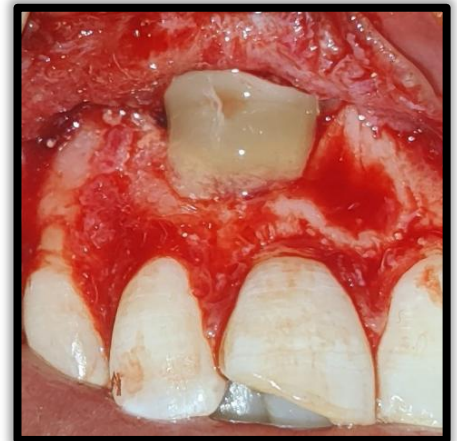
**PERIAPICAL LESION WRT  
TO 11 AND 12**



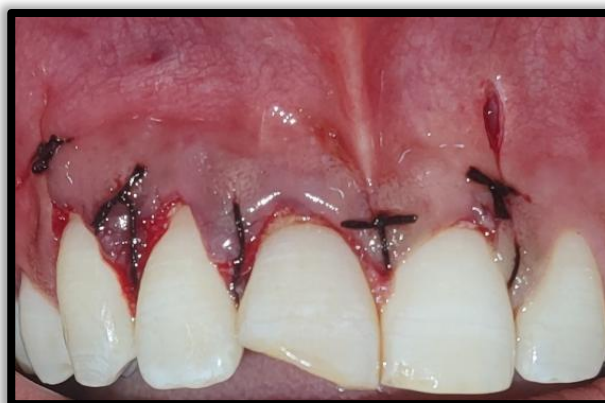**BIODENTIN PLACED OVER  
ROOT APEX WRT 11 AND 12**



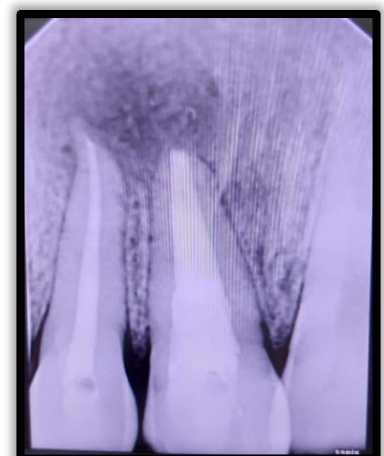**PLATELET RICH  
FIBRIN**



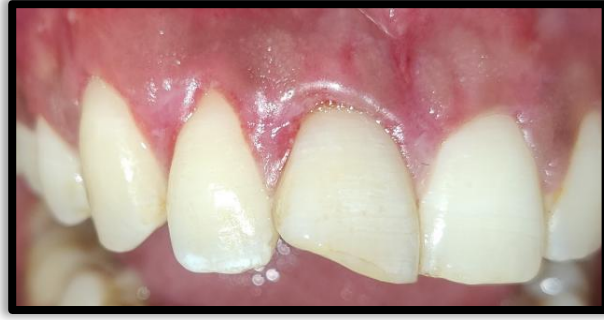**PRF PLACED OVER  
THE LESION**



**SIMPLE INTERRUPTED  
SUTURE PLACED**



**1 MONTH POST-  
OPERATIVE IOPA**



**1 MONTH POST-  
OPERATIVE VIEW**