

**CASE NO 25**

**APICECTOMY + REGENERATIVE SURGERY.**

PATIENT NAME: Mr. I. K.

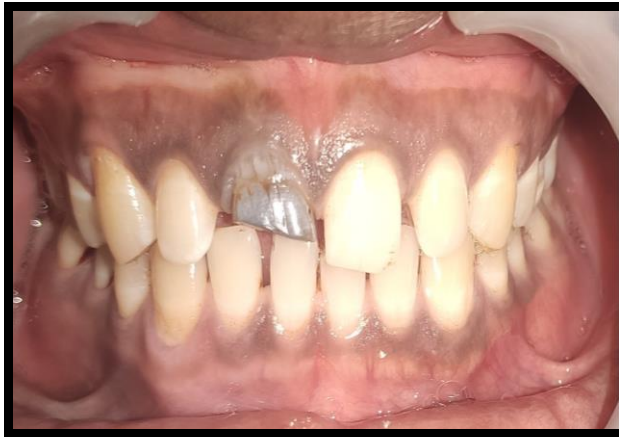AGE: 26

GENDER: M

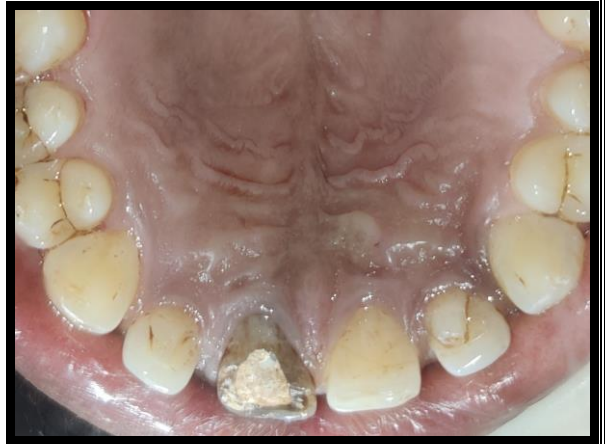OPD NO: 218097

DIAGNOSIS: Generalized Dental biofilm induced gingivitis in an intact periodontium with Endo-perio lesion with root canal with 11.

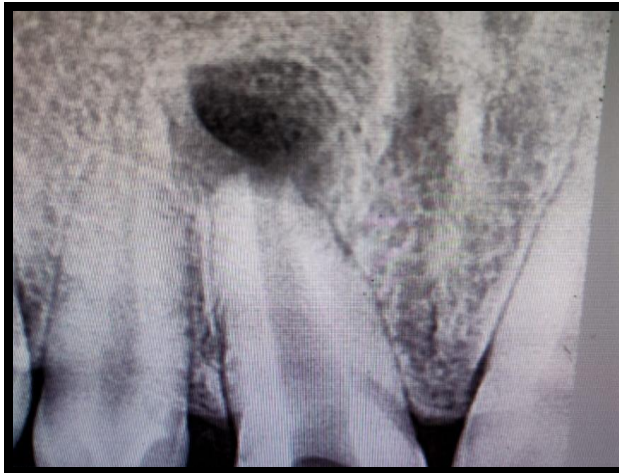TREATMENT DONE: Apicectomy & Regenerative surgery with DFDBA bone graft & GTR membrane.



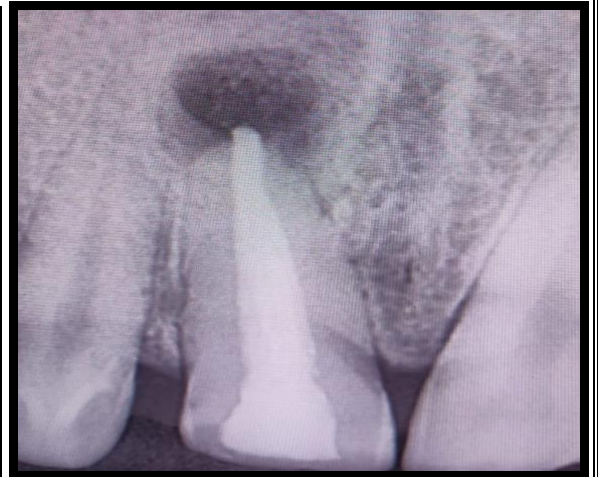
**PREOPERATIVE FRONTAL VIEW**



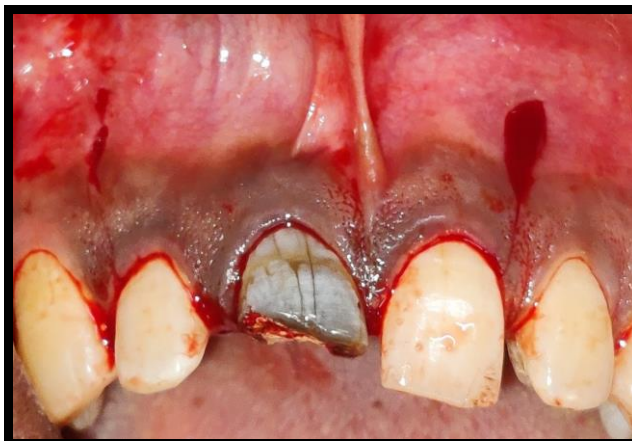**PREOPERATIVE PALATAL VIEW**



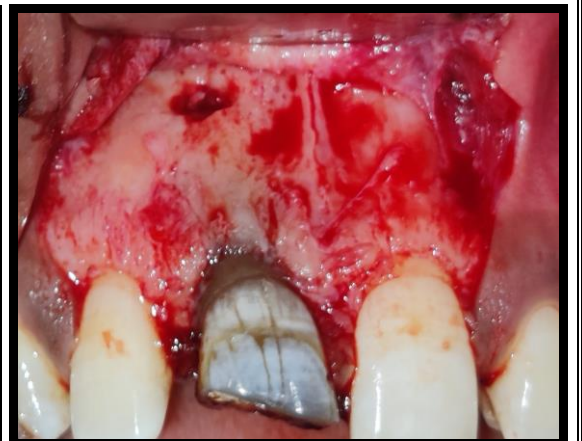
**PREOPERATIVE IOPA**



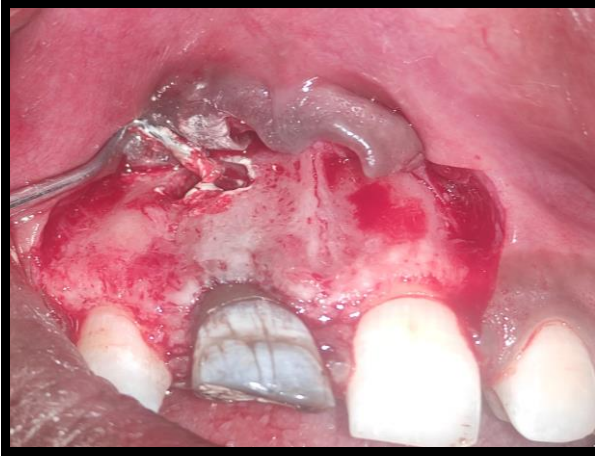**POST RCT IOPA**



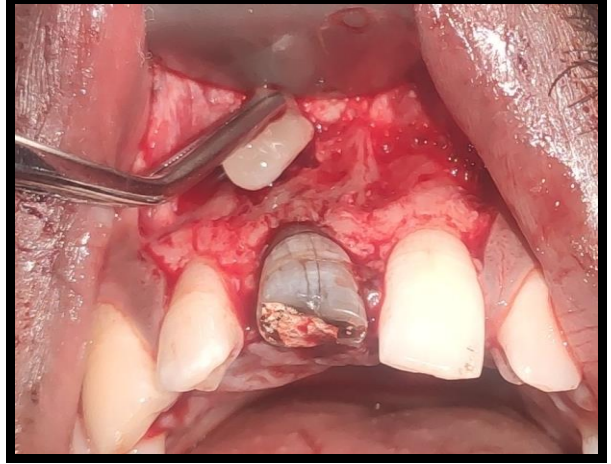
**CREVICULAR AND VERTICAL  
INCISION PLACEMENT**



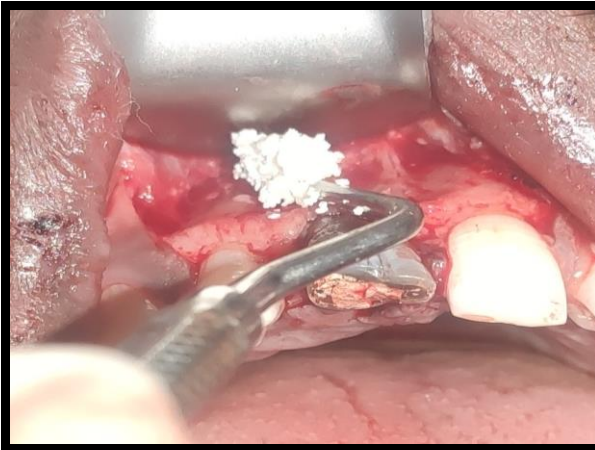
**FULL THICKNESS FLAP  
REFLECTION**



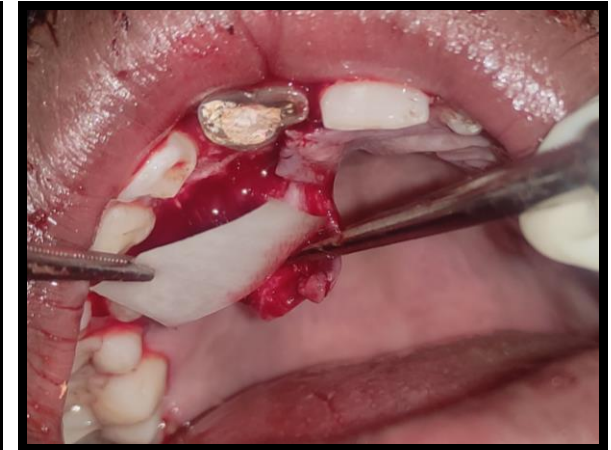**ROOT CAVITY PREPARATION  
AND BIODETINE PLACEMENT**



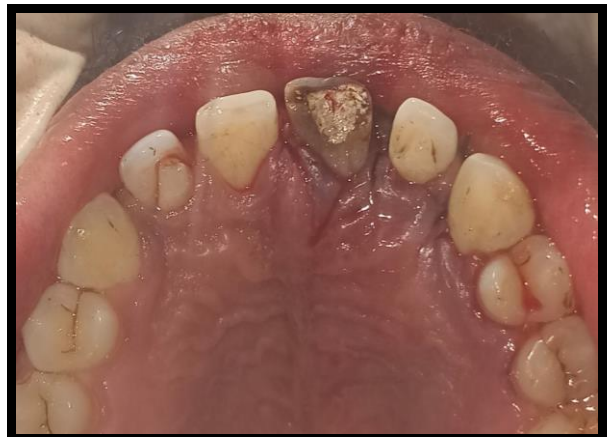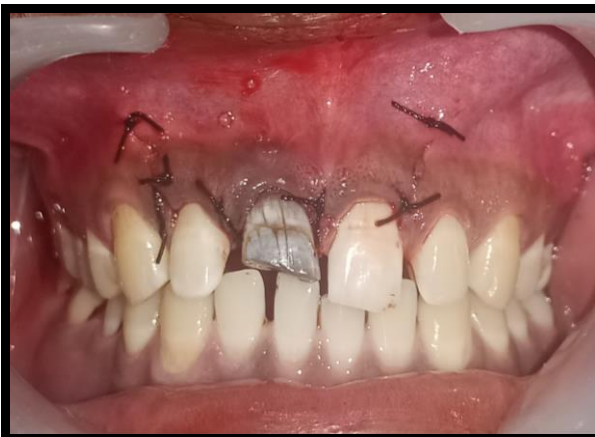**PRF PLACEMENT**



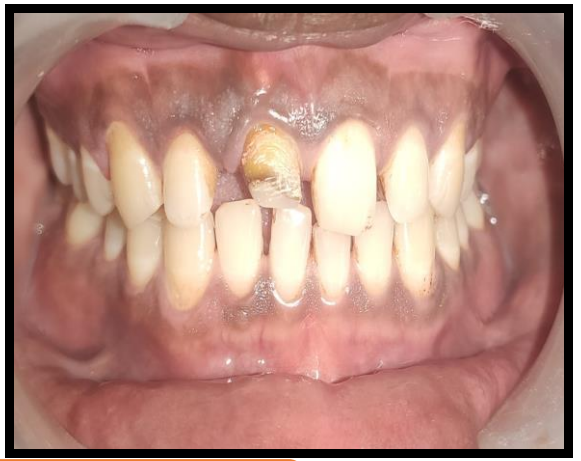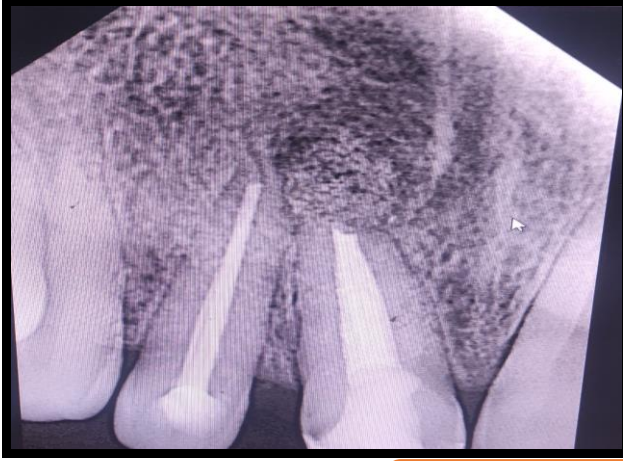**DFDBA BONE GRAFT  
PLACEMENT**



**GTR MEMBRANE PLACEMENT  
(PALATAL SIDE)**



**SUTURE PLACEMENT**



**3 month follow up**